

See discussions, stats, and author profiles for this publication at: <https://www.researchgate.net/publication/338083093>

STUDY OF PATHOLOGICAL CHANGES CAUSED BY MYCOTOXINS IN BROILERS IN AL-QURNA CITY, BASRA, IRAQ

Article · December 2019

CITATIONS

0

READS

138

3 authors, including:



Qayssar Ali Kraidi

University of Misan

9 PUBLICATIONS 16 CITATIONS

SEE PROFILE



Mazin Adeel Chayan

1 PUBLICATION 0 CITATIONS

SEE PROFILE

Some of the authors of this publication are also working on these related projects:



ACUTE TOXICOLOGICAL PATHOLOGY OF COUMAPHOS (ORGANOPHOSPHATE COMPOUNDS) IN ROCK DOVE (*Columba livia gaddi*) [View project](#)



STUDY OF PATHOLOGICAL CHANGES CAUSED BY MYCOTOXINS IN BROILERS IN AL-QURNA CITY, BASRA, IRAQ

Qayssar Ali Kraidi^{1*}, Salma Saeed Abbas² and Mazin Adeel Chayan³

¹Department of Animal Production, Faculty of Agriculture, University of Misan, Misan, Iraq

²Department of Biology, Education College for Pure Science, University of Basrah, Basrah, Iraq

³Depart. of Pathology and Poultry Diseases, College of Veterinary Medicine University of Basrah, Basrah, Iraq.

Abstract

Mycotoxins have been already identified as a major contaminants of poultry ration. Current study was carried out to detect the presence of aflatoxins and trichothecenes T-2 toxin in broiler chicks' ration and to investigate the histopathological changes in affected organs of infected birds. Samples were collected from pellet of suspected infected broiler hatchlings' farms which in Al-Qurna city depending on clinical signs of mycotoxicosis. Food samples were undergone Enzyme linked immunosorbent assay to assess the presence of aflatoxin and T-2 mycotoxins. Furthermore between 15 examined feed samples, eight were positive to aflatoxin and T-2 toxin with concentrations greater than the maximum tolerable dose 26.5 and 158.3 ppb respectively. The postmortem lesions include ascites, paleness of liver and enlarged of the kidney were noticed in chicks with 14 to 18 days. Histopathological analyses demonstrated vacuolation and necrosis of affected organs and thickening of the muscular layer of gizzard. The findings of this work indicate that most of the examined samples were complexity contaminated with both types of aflatoxin and T-2, there by their complex synergistic effects may be resulted in various histopathological changes of affected organs. Although, several samples were higher than the allowed limit; there is an urgent need for strict feeding system which ensure safety and quality of poultry feed herby to avoid mycotoxicosis and protect poultry industry and poultry consumers.

Keywords: mycotoxins; T-2; ELISA; Histopathological changes, broilers.

Introduction

Aflatoxins are a wide range of toxic metabolites mainly Produced by the fungi *Aspergillus flavus* and *Aspergillus parasiticus*. At the optimal environmental temperature and humidity, these microorganisms produce aflatoxins G1, G2, B1 and B2, among the four naturally occurring types of aflatoxins, the AFB1 is considered the most potent carcinogenic and a common contaminant of poultry feeds with a particular spread in the tropical and subtropical areas (van Egmond and Jonker 2004). Mycotoxins are source of different biological changes for instance immunosuppressive, carcinogenic, nephrotoxic and estrogenic impacts. Mycotoxin of different feed types is still to be a nearest problem to the fineness and safety worldwide; great universal attention is being concentrated on mycotoxins because feeds contamination has a deleterious influence on animal health

**Author for correspondence* : E-mail : caesar.ali@uomisan.edu.iq

(Dhanasekaran *et al.*, 2009). Poultry is very sensitive to mycotoxicosis caused by ochratoxins and aflatoxins (Anjum *et al.*, 2012). Aflatoxicosis cause huge economic losses in poultry production, which affecting the most type of birds (CAST, 2003). Aflatoxin deteriorates most of the remarkable production parameters like feed intake, feed conversion ratio, egg production and the reproductive performance of male and female birds (Hussain *et al.*, 2010). The prevalence studies on mycotoxins in feed stuff are precisely and generally applied in numerous countries such as Brazil (Rosa *et al.*, 2006), Kuwait (Beg *et al.*, 2006), Nigeria (Osho *et al.*, 2007), India (Vijayasamundeeswari *et al.*, 2009), Iran (Beheshti and Asadi, 2014) and Malaysia (Reddy and Salleh, 2011).

T-2 toxin is a secondary metabolite produced by *F. acuminatum*, *F. poae* and *F. sporotrichioides*. (Agag, 2005). Poultry and ruminants are at high risk due to the consumption of too much amounts of cereal crops in their

feed (Charoenpornsook and Kavisarasai, 2006) Poultry are more sensitive to trichothecenes than ruminants (Eriksen and Pettersson 2004). In birds, the toxic effects of T-2 toxin can be extended as genotoxic, cytotoxic and could affect the immunomodulatory, digestive and nervous system (Sokoloviæ *et al.*, 2008). In China, the T-2 toxin limit in animal feed is 0.08 mg/kg and in Canada, can in limit up to 1 mg/kg in the feed for swine and poultry. However, In Iran the accepted standard level is 25 µg/kg for cattle and poultry feed (Majid *et al.*, 2012).

In Iraq, many feed stuff, which are utilized in poultry feeds, are probable to be contaminated with afla and T-2 toxins. That may be attributed to some of the commercial feed stuff in Iraq provide appropriate conditions for fungal growth enhanced by incorrect harvesting and storage, unsanitary ways of handling and production. For above reasons, the current study aimed to investigate the contamination of poultry feed with afla toxin and T-2 toxin in Basra province–southern end of Iraq via ELISA quantification method and study the pathological changes in some organs of broilers exposed to these mycotoxins.

Materials and Method

Sample collection

Broiler feed pellet samples (500 g per ton of feed) were collected randomly from the different locations of suspected broiler farms with mycotoxicosis in AL-Qurnacity Basra province, Iraq from July to September 2017.

Mycotoxin Analyses; ELISA

The present work was done in the Center of Evaluation and Quality Control (ministry of agriculture) in AL- Qurna city of Basra province (BioTek Eliza instrument & Neogen food safety diagnostics kit). Fifteen samples of poultry feed were taken from the local suspected broiler farms in Al-Qurna district. A triplicate samples were conducted for each sample to detect the following mycotoxins (Afla toxin and T-2). The procedure included the addition of methanol to feed, shaking for 5 minutes, using filter paper and blue conjugate, washing with distilled water (substrate and red stop).

Histopathological examination;

Organs tissues (gizzards, liver and kidney) were harvested for histopathological investigations. After

sacrifice, each bird was necropsied and lesions in organs were reported. Then the examined samples were fixed in 10% formalin, embedded in paraffin and cut into slices of 4-5 mm and stained with hematoxylin-eosin (Allen, 1994).

Results

ELIZA technique

From 15 examined samples, the present study showed eight positive samples with high above the permissible limit 158.3 ppb of T-2 toxins Fig. 1 and 26.5 ppb Fig. 2 of afla toxin in examined broiler feed which taken from the studied area. Whereas the allowed limit 20ppb and 150 ppb of afla toxin and T-2 toxins respectively (US-FDA). The results revealed the presence of both mentioned toxins together in the same feed samples.

Clinical picture & postmortem examination

The clinical signs of suspected broiler chicks were depression, loss of appetite, in coordination and vitamin deficiency like symptoms Fig. 3. While the postmortem lesions ascites, paleness of liver and enlarged of the kidney Fig. 4, 5 and 6. These signs and lesions were noticed in

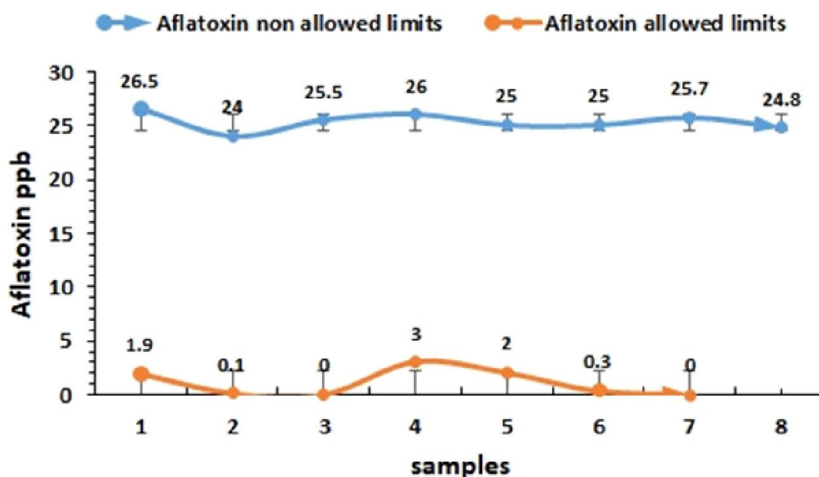


Fig. 1: Afla toxin allowed and non-allowed limits ppb.

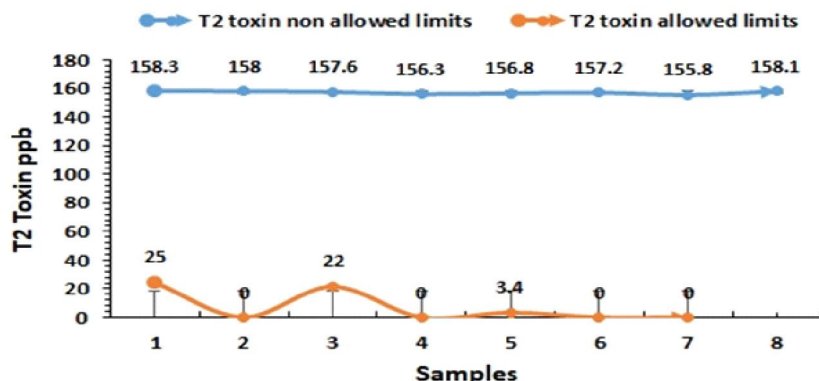


Fig. 2: T2 toxin allowed and non-allowed limits ppb.



Fig. 3: Depression of suspected infected broiler chicks with mycotoxicosis.

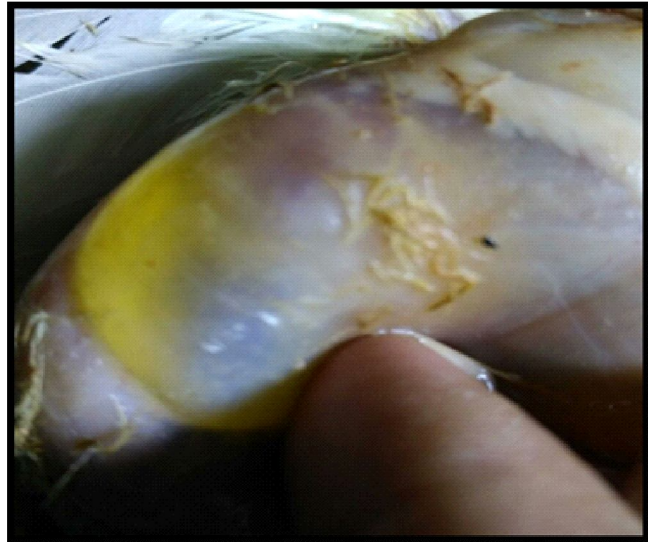

Fig. 4: Excessive Accumulation of fluid in abdominal cavity of broiler chicks taken from suspected farms

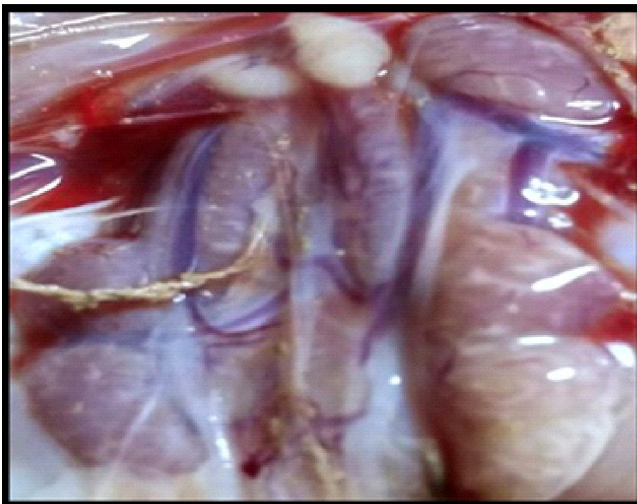


Fig. 5: Enlargement of kidney of the infected broiler chick

chicks with 14 to 18 days.

Histopathological finding;

Examined autopsies of kidney, liver and gizzard show vacuolation and necrosis of kidney tubules, congestion and vacuolation of liver mesenchyme and thickening of muscular layer of gizzard as shown in Fig. 7, 8 and 9.

Discussion

In Iraq, poultry industry represent one of the major sources of protein available to the inhabitants. Feed contaminated with mycotoxins, particularly aflatoxins, is predominantly a health and production risk for poultry. Furthermore, the residues of mycotoxins in poultry products may represent a threat to human's health through their adverse effects (Lizárraga-Paulín *et al.*, 2011, Freire *et al.*, 2007, Wild and Gong, 2010). The

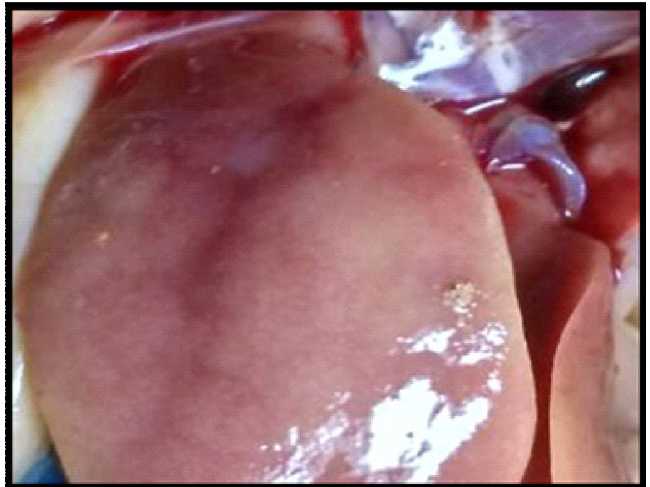


Fig. 6: Liver of the chicks, paleness and enlargement of target organ

present study revealed presence a high level of aflatoxins and T-2 (26.5 ppb and 158 ppb respectively) in broiler chicks pellet samples and this result is in agreement with the results of previous work of (AL-Saeedi, 2014), who reported presence of high percentage of contamination (77.5%, 32% and 86.2%) with aflatoxin, ochratoxins and T-2 toxins, respectively in broiler feed in Najaf and Al-Qadisiya governorate. Also (Ali *et al.*, 2017), referred to the presence of the highest contamination levels of mycotoxin in the local yellow corn in comparison with imported yellow corn in Iraq, in particularly aflatoxin were ranged from (20.1 to 157) ppb, which is higher than the acceptable levels. That may be attributed to bad storage or contaminated of imported poultry feed components. The production of aflatoxin may take place during post-harvest, processing, storage or feeding under appropriate conditions. Spite of hindering of aflatoxin

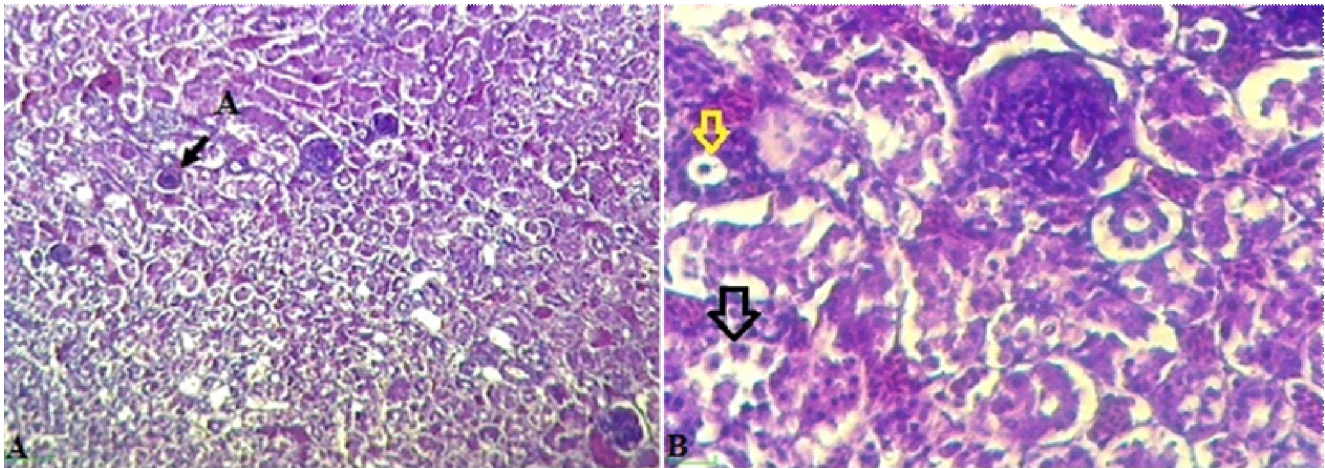


Fig. 7: A- Section of kidney showed engorgement of proximal renal tubules (A) with basophilic material (A) and sloughing of brush border of other proximal renal tubules. H&E, 100X. B- Section of kidney that showed presence of engorgement of proximal renal tubules (yellow arrow) and necrosis of renal glomerulus (black arrow). H&E, 400X.

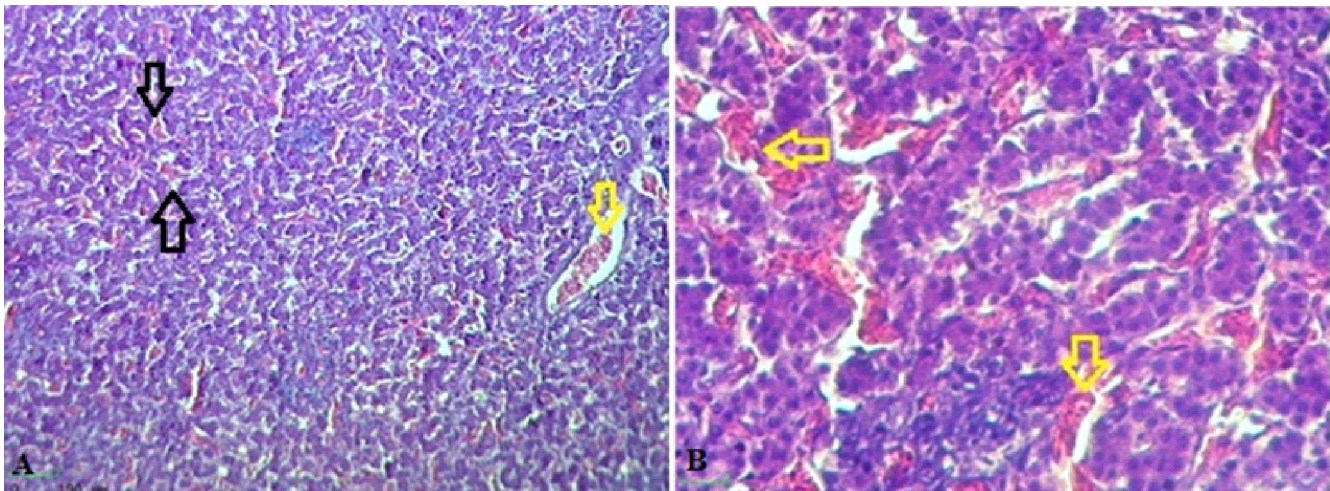


Fig. 8: A- Section of liver showed that the trabecular structure of the liver is blurred. Engorgement of the hepatic sinusoids (black arrows) and hepatic central vein (yellow arrow). H&E, 100X. B- Section of liver showed dilatation and engorgement of the hepatic sinusoids (yellow arrows). H&E, 400X.

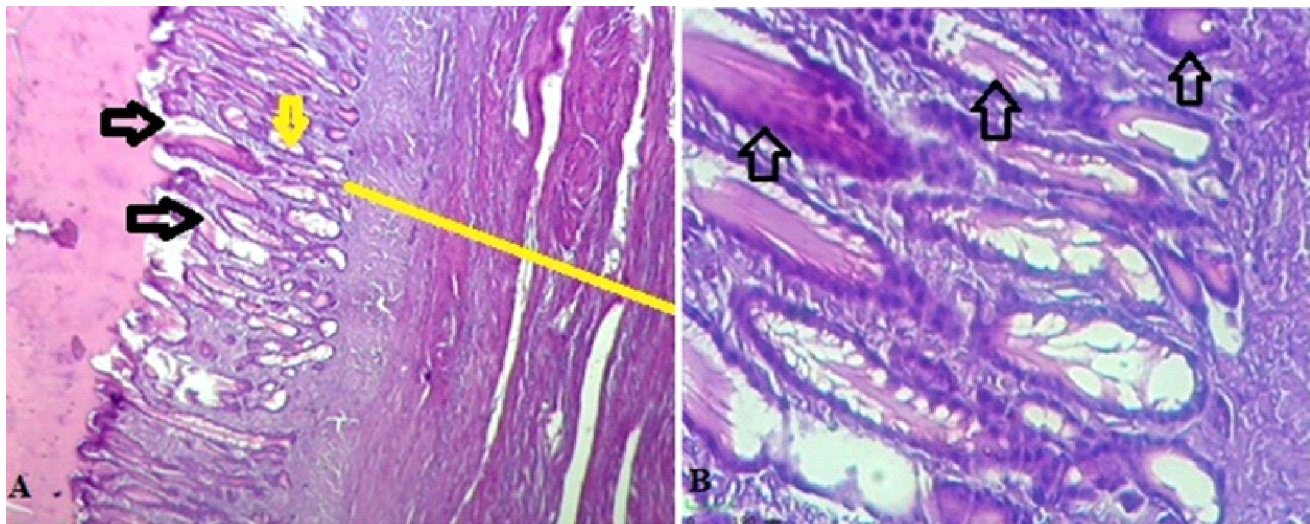


Fig. 9: A- Section of gizzard showed dilatation of the ducts of the secretory tubule (red arrow), engorgement of simple tubular gland (black arrow) and thickening of muscularis layer (yellow line). H&E, 100X. B- Engorgement of simple tubular glands (black arrow). H&E, 400X.

production in feed prior harvesting is tricky due to high humidity, it is potential to gain favorable outcome by ensuring appropriate storage (Richard, 2007).

Clinical finding and postmortem lesions revealed mycotoxicosis, which including depression, as cites in coordination, vitamins deficiencies and like liver and kidney lesions, livers may be enlarged and fatty, enteritis of variable degree and hydro pericardium, this finding consistent with that of (D'mello *et al.*, 1999).

Histopathological picture of this study exhibited, degenerative changes in the liver, kidney and hyperplasia of the gizzard. This outcome similar to that of Raja and Chidambaram (2009), who reported different pathological findings in many organs characterized by degenerative and necrotic changes were seen in the liver, kidneys, intestine, pancreas, heart, pectoral muscle, spleen and bursa of fabricious of all toxin fed chicks. In addition to, hyperplastic changes were also seen in the crop, proventriculus and gizzard. The presence of the various histopathological changes in examined organs of affected birds could be stem from the synergistic effects of afla and T-2 toxins in contaminated poultry feeds and these results in accordance with previous results reported by (Huff *et al.*, 1988) who mentioned that afla toxin and T-2 toxin can interact to produce synergistic toxicity.

In conclusion, this work indicates that most of the examined samples were contaminated with both mycotoxins (afla & trichothecenes) and the synergistic effects of them resulted in the producing of various histopathological changes in affected organs. However, several samples were higher than the allowed limit; there is a need to constant surveillance to the production and marketing chain to ensure that the quality of the feed is not put human and poultry at risk of mycotoxin exposure.

Acknowledgments

This work was supported by the Misan university research council, college of agriculture. I would like to extend my special thanks to Dr. Waleed Al-Mayyahi for his help in collection of samples.

References

Agag, B.I. (2005). Mycotoxins in foods and feeds 5-Trichothecenes AT-2 Toxin. *Assiut University bulletin for environmental researches*, **8(2)**: 641-645.

AL-Saeedi, T. A. (2014). The Study of the Contamination Range in Poultry Feeds with Mycotoxins in Najaf and Al-Qadisiya. Kufa. *Journal for Veterinary Medical Sciences*, **5**: 1-5.

Ali, M.D., M.L. AL-Musawi, F.A. Fouad, A.H. Kalif, K.G. Abdulla, H.M. Kanaan and Z.A. Hassan (2017). Comparison of

Mycotoxin Contamination levels of Local and Imported Corn in Iraq. *American Scientific Research Journal for Engineering, Technology and Sciences*, **28(1)**: 181-6.

Allen, T.C.(1994). Hematoxylin and eosin. In: Laboratory Methods in Histotechnology. *American Registry of Pathology*, Washington, 53-58.

Anjum, M.A., S.H. Khan, A.W. Sahota and R. Sardar (2012). Assessment of afla toxin B1 in commercial poultry feed and feed ingredients. *Journal of Animal and Plant Sciences*, **22**: 268-72.

Beg, M.U., M. Al-Mutairi, K.R Beg, H.M. Al-Mazeedi, L.N. Ali and T. Saeed (2006). Mycotoxin in poultry feed in Kuwait. *Archives of Environmental Contamination and Toxicology*, **50(4)**: 595-602.

Beheshti, H.R. and M. Asadi (2014). Afla toxins in animal feed in Iran. *Food Additives & Contaminants: Part B*, **7(1)**: 40-42.

Charoenpornsook, K. and P. Kavisarasai (2006). Mycotoxins in animal feedstuffs of Thailand. *Current Applied Science and Technology*, **6(1)**: 25-28.

Council for Agricultural Science. (2003). Mycotoxins: risks in plant, animal and human systems. **139**. Council for Agricultural.

D'mello, J.P.F., C.M. Placinta and A.M.C. Macdonald (1999). Fusarium mycotoxins: A review of global implications for animal health, welfare and productivity. *Animal feed science and technology*, **80(3-4)**: 183-205.

Dhanasekaran, D., A. Panneerselvam and N. Thajuddin (2009). Evaluation of aflatoxicosis in hens fed with commercial poultry feed. *Turkish Journal of Veterinary and Animal Sciences*, **33(5)**: 385-91.

Eriksen, G.S. and H. Pettersson (2004). Toxicological evaluation of trichothecenes in animal feed. *Animal Feed Science and Technology*, **114(1-4)**: 205-239.

Freire, F.C.O., I.G.P. Vieira, M.I.F. Guedes and F.N.P. Mendes (2007). Micotoxinas: Importância Alimentação e na Saúde Humana e Animal, 110th ed.; *Embrapa Agroindústria Tropical*, : Fortaleza, Brazil, 1-48.

Huff, W. E., R.B. Harvey, L.F. Kubena and G.E. Rottinghaus (1988). Toxic synergism between afla toxin and T-2 toxin in broiler chickens. *Poultry Science* **67(10)**: 1418-1423.

Hussain, Z., M.Z. Khan, A. Khan, I. Javed, M.K. Saleemi, S. Mahmood and M.R. Asi (2010). "Residues of afla toxin B1 in broiler meat: Effect of age and dietary afla toxin B1 levels." *Food and Chemical Toxicology*, **48(12)**: 3304-3307.

Lizárraga-Paulín, E.G., E. Moreno-Martínez and S.P. Miranda-Castro (2011). Afla toxins and their impact on human and animal health: An emerging problem. In *Afla toxins Biochemistry and Molecular Biology*, 255-282.

Majid, R.I., F. Abbas Ali and B.B. Ghasem (2012). Survey of T-2 toxin present in cereals destined for human consumption. *Jundishapur Journal of Microbiology*, **3**: 497-501.

- Osho, I.B., T.A.M. Awoniyi and A.I. Adebayo (2007). Mycological investigation of compound poultry feeds used in poultry farms in south west Nigeria. *African Journal of Biotechnology*, **6(15)**: 1833-1836.
- Raja, K. and B. Chidambaram (2009). Histopathological changes in broiler chickens fed aflatoxin and cyclopiazonic acid. *Veterinarski Arhiv*, **79**: 31-40.
- Reddy, K.R.N. and B. Salleh (2011). Co-occurrence of molds and mycotoxins in corn grains used for animal feeds in Malaysia. *Journal of Animal and Veterinary Advances*, **10(5)**: 668-673.
- Richard, J.L. (2007). Some major mycotoxins and their Mycotoxicosis. An overview. *International Journal of Food Microbiology*, **119(1-2)**: 3-10.
- Rosa, C.A.R., J.M.M. Riberio, M.J. Fraga, M. Gatti, L.R. Cavaglieri, C.E. Magnoli, A.M. Dalcero and C.W.G. Lopes (2006). Mycoflora of poultry feed and ochratoxins producing ability of isolated *Aspergillus* and *Penicillium* species. *Veterinary Microbiology*, **113(1-2)**: 89-96.
- Sokoloviæ, M., G.V. Verica and S. Borka (2008). "T-2 toxin: incidence and toxicity in poultry." *Arhiv za Higijenu i Daitoksikologiju*, **59(1)**: 43-52.
- Van Egmond, H.P. and M.A. Jonker (2004). Worldwide regulations on aflatoxins-the situation in 2002. *Journal of Toxicology Toxin Reviews*, **23(2-3)**: 273-93.
- Vijayasamundeeswari, A., M. Mohankumar, M. Karthikeyan, S. Vijayanandraj, V. Paranidharan and R. Velazhahan (2009). Prevalence of aflatoxin B1 contamination in pre and post-harvest corn kernels, food products, poultry and livestock feeds in Tamil Nadu, India. *Journal of Plant Protection Research*, **49(2)**: 221-224.
- Wild, C.P. and Y.Y. Gong (2010). Mycotoxins and human disease: A largely ignored global health issue. *Carcinogenesis*, **31**: 71-82.