



Journal Homepage: - www.journalijar.com
**INTERNATIONAL JOURNAL OF
 ADVANCED RESEARCH (IJAR)**

Article DOI: 10.21474/IJAR01/2711
 DOI URL: <http://dx.doi.org/10.21474/IJAR01/2711>



RESEARCH ARTICLE

A study of the effect of *Nigella sativa* (Black seeds) on pyrazinamide and anti-tuberculosis drugs induced hepatotoxicity in rabbits.

Rasha K. Khudur¹ and Jawad H. Ahmed².

1. Assistant lecturer, B.Sc. Pharmacy, Department of Pharmacy, College of Medicine, University of Misan, Iraq.
2. Assistant Professor, MBChB, PhD, Department of Pharmacology, College of Medicine, University of Basrah, Iraq.

Manuscript Info

Manuscript History

Received: 22 October 2016
 Final Accepted: 26 November 2016
 Published: December 2016

Key words:-

Pyrazinamide, INH, Rifampicin, *Nigella sativa*, Oxidative stress, Antioxidant.

Abstract

Hepatotoxicity is a real challenge to physicians concerned intuberculosis treatment. It is frequently blamed for therapy failure and emergence of bacterial resistance and sometimes fatal. In the absence of a drug which can prevent hepatotoxicity, herbal medications offer an alternative remedy to minimize this side effect. The study was designed to evaluate the effect of *Nigella sativa* (NS), a medicinal plant known for its hepatoprotective effect against hepatotoxicity induced by Pyrazinamide (PZA) 350 mg/kg alone or in combination with other anti-tuberculosis drugs (anti-TB). Anti-TB drugs contain PZA 350 mg/kg + INH 50 mg/kg + Rifampicin (RIF) 100 mg/kg. Six groups of rabbits (6 animals in each) were treated orally for 12 days as follow: Normal saline (control), NS, PZA, (PZA+NS), (Anti-TB drugs), and (Anti-TB + NS). Liver enzymes, S. Glutathione (GSH), liver tissue (GSH) and Malondialdehyde (MDA) were estimated and liver histology was examined. PZA and anti-TB drugs increased liver enzymes, increased MDA and decreased GSH with histopathological changes suggestive of hepatotoxicity. Treatment with NS significantly changed liver enzymes, GSH, MDA and histopathological changes toward normal values. Conclusions: NS due to its antioxidant effect is protective against hepatotoxicity induced by PZA and anti-TB drugs.

Copy Right, IJAR, 2016.. All rights reserved.

Introduction:-

Hepatotoxicity is frequently reported as the most serious adverse effect of antituberculosis (anti-TB) therapy as it is associated with a high rate of morbidity and mortality (Sonika & Kar 2012). Hepatotoxicity adversely affects compliance to the drugs, markedly increases rate of treatment failure, resulting in relapse of the disease or emergence of bacterial resistance (Schaberg et al., 1996). Hepatotoxicity was reported with most anti-TB drugs such as INH, PZA and RIF. Patients treated for tuberculosis are at increased risk of hepatotoxicity since anti-TB drugs are usually given in combination. It has been reported that the incidence of hepatotoxicity increased 5 times from 6% with INH alone to 30% when INH is given in combination with other anti-TB drugs particularly with RIF (Taneja & Kaur 1990).

In view of lacking of an agreeable drug with a hepatoprotective potential, herbs may offer an alternative tool in preventing drug induced liver injury (Chaudhary et al., 2010). Among these herbs, NS (Black Cumin, Black seeds)

Corresponding Author:- Rasha K. Khudur.

Address:- Assistant lecturer, B.Sc. Pharmacy, Department of Pharmacy, College of Medicine, University of Misan, Iraq.

is shown to have protective effect against INH (Hassan et al., 2012), CCL4 (Kanter et al., 2005) induced hepatotoxicity. It is thought that the protective effect of NS and its active constituents is attributed mainly to antioxidant potentials (Burits & Bucar 2000; El-Dakhkhny et al., 2000). The present study was designed to investigate the possible protective effect of NS in hepatotoxicity induced by PZA alone or in combination with anti-TB drugs in rabbits.

Materials and Methods:-

Preparation of NS:-

The seeds of NS were purchased from a local herbalist shop in the town of Basrah, authenticated by an expert herbalist and a voucher specimen was kept in the Department of Pharmacology for future reference. The seeds were powdered by an electric grinder and suspended in normal saline (Haidylena, Egypt) to prepare a suspension (1 g/5 ml). The suspension was given to the rabbits at a dose of 1g/kg. Before dosing, each rabbit was isolated in a special restriction cage which prevents the animal from approaching its dropping to ensure fasting condition. After treatment, the rabbits were returned back to their original cages and kept on restricted diet containing clover and lettuce.

Preparation of drugs:-

Preparation of PZA:-

Five tablets of PZA (T&D Germany, each tablet contains 500mg) were crushed by porcelain mortar into a fine powder, and because of poor solubility it was suspended in 25 ml normal saline to obtain a concentration of 100 mg/ml. The calculated dose of PZA for each rabbit was 350mg/kg.

Preparation of INH:-

Five tablets of INH (Versa Pharm, USA, each tablet contains 100mg) were crushed by porcelain mortar and dissolved in 20 ml normal saline to prepare oral solution (25 mg/ml) then given to the rabbit in combination with other anti-TB drugs at a dose of 50mg/kg.

Preparation of RIF:-

RIF is presented as capsules (Actavis, UK, each capsule contains 300mg). A powder from five capsules were dissolved in 30 ml normal saline to obtain a concentration of 50 mg/ml of RIF and a dose of 100mg/kg is calculated for each rabbits.

Preparation of anti-TB drugs:-

A mixture of PZA 350mg/kg, INH 50 mg/kg and RIF 100mg/kg (7.5 ml total) was prepared for each rabbit.

Handling of animals and Experimental design:-

Thirty six male domestic rabbits weighing 1.5-2 kg were used for the study. The animals were housed in the animal house at the College of Medicine under conditions of controlled temperature with free access to water and food. Fifteen days before the experiment, the animals were kept in separate cages for acclimatization. The animals were handled with sympathy in harmony with the internationally accepted guidelines for handling laboratory animals (National Institutes for Health USA publication, 1985), and all possible measures were practiced to minimize pain and discomfort during experimentation. The study protocol was presented to the ethical committee of the College of Medicine for approval and carried out between November 2015 and April, 2016.

The animals were divided into six groups, six animals in each group. Group 1 (control group) were given normal saline orally (3 ml/kg/day); group 2 (NS group) were treated with suspension of NS orally (1g/kg/day); group 3 (PZA group) in which the animals were given a single dose of PZA (350 mg/kg/day) orally; group 4 (PZA + NS) were treated with oral suspension of NS (1g/kg/day) followed by suspension of PZA (350mg/kg); group 5 (anti-TB drugs), the animals were given a combination of PZA 350 mg/kg, RIF 100 mg/kg, INH 50 mg/kg orally; group 6 (NS + anti-TB drugs) the rabbits were given oral suspension of NS (1g/kg/day) followed by oral suspensions of anti-TB drugs at the same dosing schedule.

All treatments were given orally for 12 days, at day 13 of the experiment, the animals were sacrificed after one night of fasting.

Blood Sampling and Tissue Handling:-

Five milliliters of blood were taken directly from the heart under light ether anesthesia; blood samples were transferred to anticoagulant free plastic tubes, allowed to clot, centrifuged at 3000 rpm for 15 min to isolate the

serum for estimating liver function tests and(GSH). The rabbits were then sacrificed; liver specimens were obtained for the measurements of MDA and GSH and for histopathological examination.

Laboratory Measurements:-

Measurement of liver enzymes:-

Measurement of serum aspartate aminotransferase (S.AST), serum alanine aminotransferase (S.ALT), serum alkaline phosphatase (S.ALP) was estimated by commercially available kits (Biolabo reagents, Biolabo SA, France).

Preparation of liver homogenates:-

Liver tissues were homogenized in cold phosphate buffer saline (pH = 7.4) using Hiedolph electrical homogenizer, Korea) at 6 000 rpm for 20 minutes to obtain 10% liver homogenate

Estimation of liver MDA:-

MDA ELISA kit specific for rabbits was used for estimating MDA. This technique utilizes anti-MDA monoclonal antibody and MDA-HRP conjugate.

Estimation of serum and liver reduced GSH:-

GSH levels of liver homogenates were measured by ELISA Kit specific for rabbits (Cusabio reagents, Cusabio Laboratories, Wuhan, China). This technique employs double antibody sandwich technique. ELISA (Huma Reader HS, Germany) was used for the analysis.

Histopathological Examination:-

The slides were prepared in duplicates from liver specimens. Hematoxylin and eosin (H&E) were used for staining. The slides were coded and blindly examined by a senior histopathologist using light microscopy (Olympus CX-series). Histopathological changes were graded as 0 (normal), 1(mild), 2 (moderate), and 3(severe), for 0, 25, 50, and 75% histopathological changes of fields examined respectively.

Statistical Analysis:-

Statistical analysis was performed with the SPSS 20 statistical package for social sciences and Excel 2013. Descriptive statistics for the numerical data were formulated as mean and standard error mean (Mean \pm SEM). Numerical data were analyzed using independent Student's (t-test) for group's comparison. P-value < 0.05 is considered significant.

Results:-

The effect on S. AST:-

There was a significant increase in the level of S. AST in the group of rabbits treated with PZA for 12 days. The level increased from (23 \pm 2.15) U/L in the control group to (56.17 \pm 4.74)U/L in the group treated with PZA, P=0.05. Treatment with NS combined with PZA significantly lower the level of S. AST toward the control value (Table 1).

Treatment with anti-TB drugs increased S. AST to a level slightly and insignificantly higher than that caused by PZA alone and again treatment with NS combined with anti-TB drugs significantly lower S.AST compared to the value caused by anti-TB drugs but the level was higher than the control (Table 1).

The effect on S. ALT:-

The same pattern of changes of S.AST was observed with S. ALT. The level of S. ALT was significant increased from (87.5 \pm 6.46) U/L in the control group to (122.83 \pm 4.69) U/L in the group treated with PZA and the combination NS with PZA reduced the level significantly to (105.17 \pm 6.37) U/L, P=0.05 which was still higher than the control value (Table 1).

The level of S.ALT was increased by treatment with the combination of Anti-TB and further decreased when NS used in combination with the anti-TB drugs (Table 1).

The effect on S. ALP:-

S. ALP levels were significantly increased with anti-TB treatments and decreased toward the control values when NS was used in combination (Table 1).

The Effect of Treatments on MDA Level in liver homogenate:-

The mean control value of MDA in liver homogenate was (0.795 ± 0.11) mmol/g, which was increased significantly to (2.34 ± 0.44) mmol/g with PZA, $P=0.007$. The level was significantly decreased to (0.38 ± 0.17) mmol/g when NS was used in combination with PZA, $P=0.002$. Similarly, the level of MDA in liver homogenate was increased with anti-TB drugs to an extent greater than that with PZA alone and was significantly decreased toward the control value when NS was used with the anti-TB drugs.

The Effect of Treatments on GSH Level in liver homogenate:-

The mean control value of GSH in liver homogenate was (39.08 ± 4.85) mg/ml, which was significantly decreased to (23.78 ± 3.74) mg/ml in the group treated with PZA. $P=0.05$. The level was elevated to 37.2 ± 3.94 mg/ml when NS was given in combination with PZA.

Treatment with anti-TB drugs decreased GSH in liver homogenate to a level which is significantly lower than the control. The level was increased again significantly when NS was used in combination with anti-TB drugs (Table 2).

The Effect of Treatments on GSH Level in the serum:-

There was a significant reduction in the serum level of GSH in the group treated with PZA compared to the control (4.72 ± 1.01 mg/ml vs. 2.03 ± 0.55 mg/ml), $P=0.05$. The level of serum GSH was significantly increased to a level approaching the control value when PZA was given in combination with NS.

There was a greater reduction in serum GSH in the group treated with anti-TB drug which was increased by combining anti-TB and NS, however, the increase in level of serum GSH was small and did not reach the value of the control (Table 2).

Histopathological examination:-**Control group:-**

There were no histopathological changes observed in all animals in the control group as well as in the NS treated group and labelled as score zero. Representative histopathological slides are presented in (Fig 1a,b, Table 3)

PZA group:-

Histopathological features were observed in liver specimens in all animals ($n=6$) treated with PZA; mild (score 1) in 5 animals, and one animal with moderate changes (score 2) (Fig 2a). The histopathological changes were as follow:

1. vascular congestion
2. portal and periportal chronic inflammatory infiltrate forming bridges between the central and portal area.
3. ductular proliferation with moderate hydropic degeneration and lymphocytic infiltration.

PZA + NS:-

Treatment with NS + PZA had resulted in decreasing the severity of histopathological changes; in 3 animals, the changes disappeared completely and mild changes were seen in 3 animals (Fig 2b, Table 3)

Anti-TB group:-

Histopathological changes were observed in all treated animals with anti-TB drugs ($n=6$); 3 animals showed mild changes (score 1), 2 animals with moderate changes (score 2) and one animal with severe changes (Fig 3a, Table 3).

The changes were:

1. severe hepatocyte hydropic degeneration
2. hemorrhage with fibrosis
3. vascular congestion,
4. periportal bridging with scattered hepatocytic vacuolation

Anti-TB + NS:-

Treatment with NS + anti-TB had resulted in reducing the severity of changes; in 2 animals no changes were detected, and in 4 animals mild changes were observed (Fig 3b, Table 3).

Acknowledgement:-

The authors would like to thank Assistant Professor SS Al-Haroon, Department of Pathology and Forensic Medicine, University of Basrah for help in histopathological examination.

Discussion:-

Hepatotoxicity is the most life threatening complication of the first line anti-TB therapy, which results in non-compliance with treatments, failure of therapy and emergence of resistant strains of mycobacterium tuberculosis. PZA which is a first line antituberculosis drug used in combination with other drugs, is associated with elevation in liver enzymes which may end in liver failure (Shu et al., 2013).

The rabbit was used as a convenient model for inducing hepatotoxicity. The doses of antituberculous drugs were prepared by crushing 5 tablets to account for active ingredient variability in the tablets. Oral route was chosen for drug administration to mimic human intake of these medications. Two hours spacing were left between NS and anti-TB dosing to account for drug interaction at the level of absorption from the gastrointestinal tract. The drugs were prepared at high doses which exceeded the doses specified for human to ensure induction of hepatotoxicity and in the same time is able to confirm activity of drugs which possibly oppose toxicity (Eminzade et al., 2008).

In the present study, marked increase in liver enzymes in the serum (AST, ALT and ALP) was noticed after PZA and in the combination with anti-TB drugs which indicates liver damage. Liver enzymes are specific to the liver and their elevation are related to the degree of hepatic damage and result from a defect in hepatocyte cell membrane with altered membrane permeability resulting in leakage of large quantities of enzymes into the blood stream (Aubrecht et al., 2013).

Liver damage is further confirmed by histopathological examination. Liver tissues appeared normal in the control and in NS treated groups, while features of liver toxicity were noticed in PZA treated group and slightly more in intensity in the group treated with the combination of anti-TB drugs. Two possible mechanisms of PZA induced hepatotoxicity were proposed; first, toxic metabolites including pyrazinoic acid (PA) and 5-OH-pyrazinoic acid (5-OH-PA) (Shih et al., 2013) which cause direct toxicity to the liver; second, oxidative stress as a result of generation of free radical species is also reported (Walubo et al., 1995).

In the present study, PZA increased the level of MDA in liver tissue homogenate with a marked reduction in GSH levels in both liver tissue homogenate and the serum which provides an evidence of oxidative potential of PZA (Loots et al., 2005).

The observed hepatotoxicity with the combination of anti-TB drugs as illustrated by the rise in MDA and reduction in GSH with further confirmation by histopathological examination, was slightly greater than that observed with PZA alone. This basically reflects summation of toxicities of single drugs used in the combination. In addition, RIF as a potent enzyme inducer may critically induce INH and PZA metabolism resulting in formation of hydrazine and isonicotinic acid metabolites which are hepatotoxic (Askgaard et al., 1995; Tostmann et al., 2008).

There is increasing evidence that NS has a powerful free radical scavenging activities and many of its pharmacological effects are attributed to its antioxidant properties (Burits & Bucar 2000). It has been shown that NS, in animal studies, can protect the liver from insult produced by CCL4 (Kanter et al., 2005), INH (Hassan et al., 2012) or ethanol (Develi et al., 2014). In the present study, NS has been shown to prevent hepatotoxicity induced in rabbit model by PZA and also in the group treated with the combination of anti-TB drugs. This indicates that NS has a powerful hepatoprotective effects not only against single drug insult such as PZA but also protective against hepatotoxicity induced by the combination of anti-TB drugs which are known for its hepatotoxic potentials.

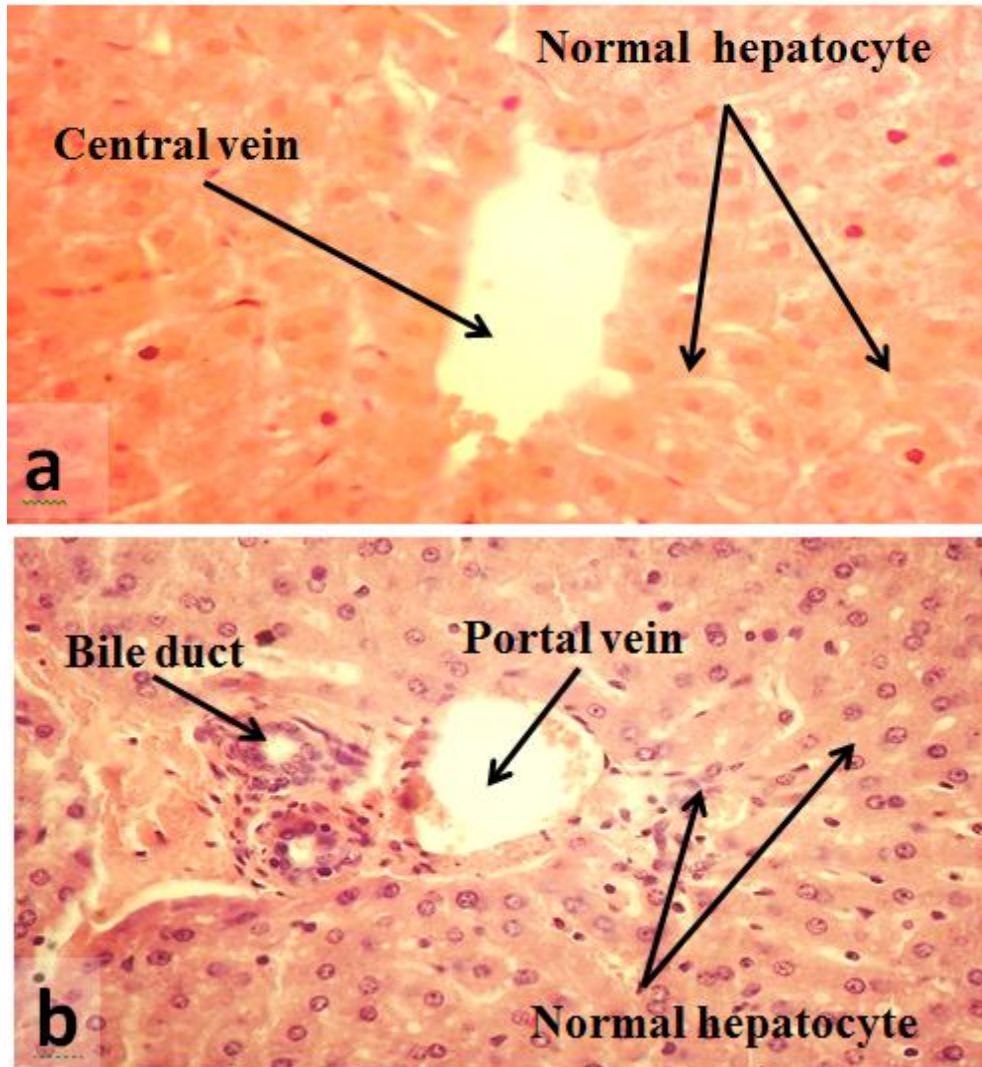


Fig 1. Representative slides of the liver for the rabbits in the control group (a), NS (b). Hepatocytes appeared normal with normal portal vein, bile duct and central vein (H&E X400).

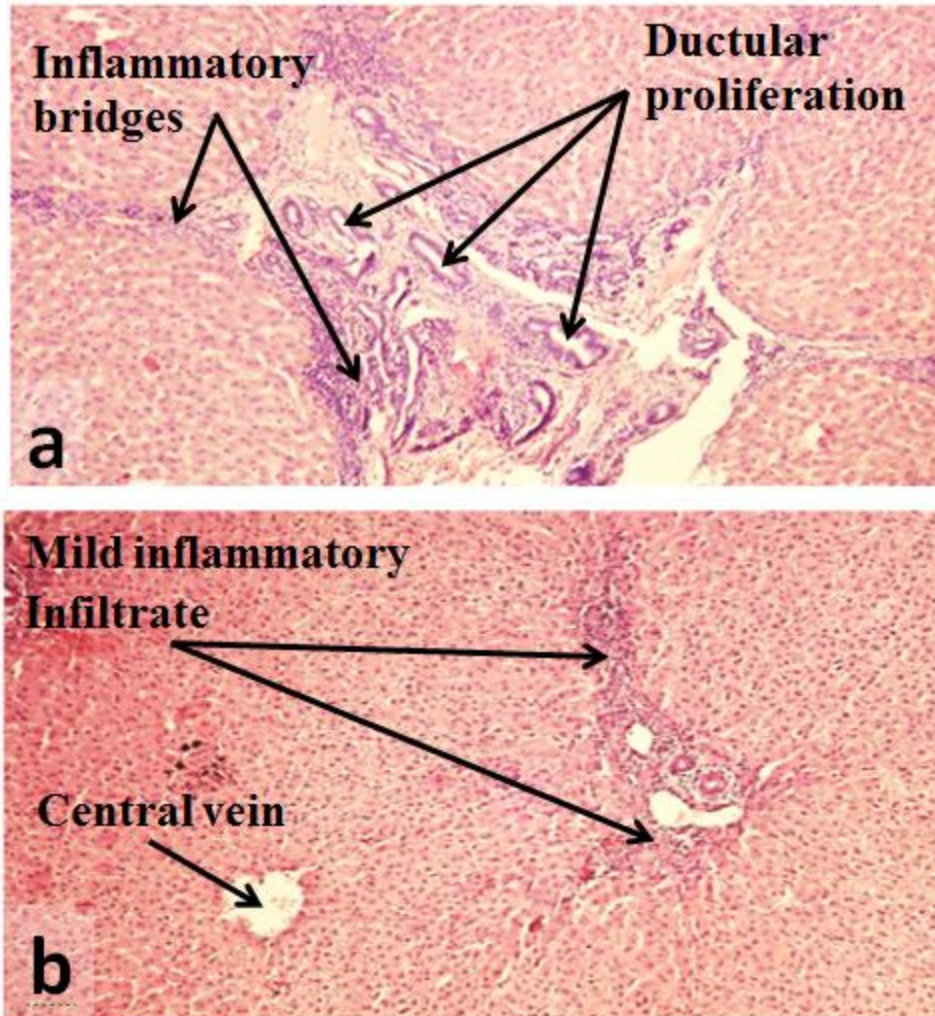


Fig 2. (a) Liver tissue of a rabbit treated with PZA which showed portal and periportal chronic inflammation, inflammatory bridges between the central and portal area and ductular proliferation. (b) liver tissue of a rabbit treated with PZA + NS, liver cells look normal apart from mild lymphocytic infiltration (H&E X100).

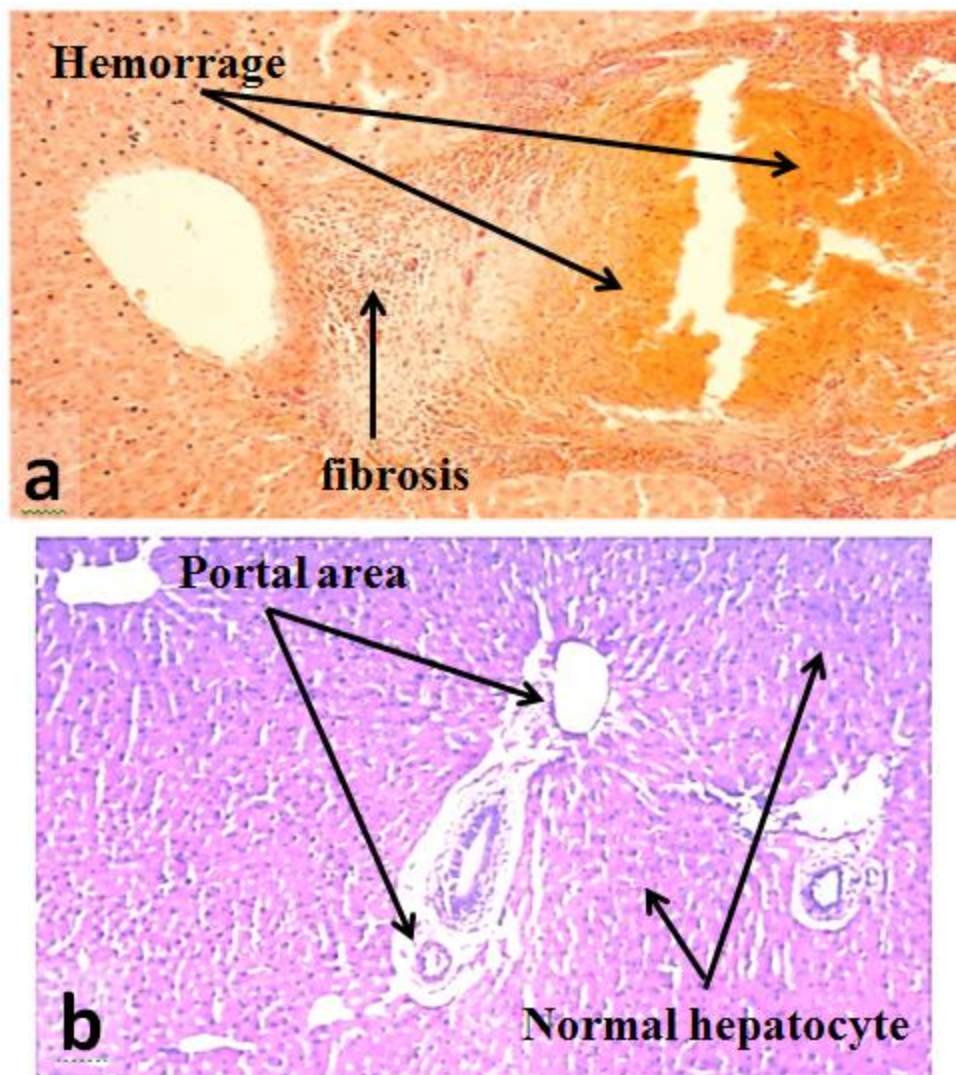


Fig 3. (a) a liver tissue of a rabbit treated with a combination of Anti-TB drugs which showed hemorrhage with fibrosis with chronic lymphocytic infiltration with periportal bridging. (b) a liver tissue of a rabbit treated with Anti-TB drugs + NS. Hepatocytes and portal area appeared normal without signs of inflammation (H&E X100).

Table 1. The effect of NS on the serum level of liver enzymes (Mean \pm SEM).

	AST (U/L)	ALT U/L)	ALP (U/L)
Control	23 \pm 2.15	87.5 \pm 6.46	50.33 \pm 7.76
NS (1g/kg/d)	26.17 \pm 2.76	81.17 \pm 9.48	58.0 \pm 6.23
PZA (350 mg/kg/d)	56.17 \pm 4.74 ^(a)	122.83 \pm 4.69 ^(a)	74.5 \pm 5.51 ^(a)
PZA+NS	17.5 \pm 3.33 ^(b)	105.17 \pm 6.37 ^(b)	33.5 \pm 2.88 ^(b)
Anti-TB	62.17 \pm 6.15 ^(c)	128.83 \pm 7.57 ^(c)	80.17 \pm 4.53 ^(c)
Anti-TB+NS	35.67 \pm 5.68 ^(d)	90.5 \pm 6.33 ^(d)	52.67 \pm 6.14 ^(d)

NS: Nigella sativa, PZA: pyrazinamide, Anti-TB: anti-tuberculosis drugs. (a): significantly higher than the corresponding value of the control (P=0.05), (b): significantly lower than the corresponding value of PZA (P=0.05), (c): significantly higher than the corresponding value of the control (P=0.05), (d): significantly lower than the value of the combination of anti-TB drugs (P=0.05).

Table 2. The effect of NS on parameters of oxidative stress in serum and liver tissue homogenate (Mean \pm SEM).

	Tissue MDA (mmol/gm)	Tissue GSH (mg/ml)	Serum GSH (mg/ml)
Control	0.795 \pm 0.11	39.08 \pm 4.85	4.72 \pm 1.01
NS (1g/kg/d)	1.03 \pm 0.24	29.12 \pm 1.85	2.83 \pm 0.99
PZA (350 mg/kg/d)	2.34 \pm 0.44 ^(a)	23.78 \pm 3.74 ^(e)	2.03 \pm 0.55 ^(e)
PZA+NS	0.38 \pm 0.17 ^(b)	37.23 \pm 3.94 ^(f)	3.97 \pm 0.56 ^(f)
Anti-TB	3.20 \pm 0.34 ^(c)	20.24 \pm 1.49 ^(g)	0.98 \pm 0.12 ^(g)
Anti-TB+NS	0.62 \pm 0.12 ^(d)	34.51 \pm 1.77 ^(h)	2.39 \pm 0.59 ^(h)

NS: Nigella sativa, PZA: pyrazinamide, Anti-TB: anti-tuberculosis drugs. (a): significantly higher than the corresponding value of the control (P=0.007), (b): significantly lower than the PZA value (P=0.002), (c): significantly higher than the corresponding value of the control (P=0.001), (d): significantly lower than the Anti-TB value (P=0.001) (e) : significantly lower than the corresponding value of the control (P=0.05), (f): significantly higher than the corresponding value of PZA (P=0.05), (g): significantly lower than the corresponding value of the control (P=0.05), (h): significantly higher than the value of the combination of anti-TB drugs (P=0.05).

Table 3. Scores of histopathological changes of liver damage induced by PZA, Anti-TB drugs and the effect of NS on these changes in rabbits.

Number of animals						
Scores	Control	NS	PZA	PZA+NS	Anti-TB	Anti-TB+NS
0	6	6	0	3	-	2
1	0	0	5	3	3	4
2	0	0	1	0	2	0
3	0	0	0	0	1	0

n = 6 , Scores 0, 1, 2 and 3 are for normal, mild, moderate and severe changes respectively). NS: Nigella sativa, PZA: pyrazinamide, Anti-TB: anti-tuberculosis drugs

Conclusion:-

NS has a protective effect against liver damage caused by PZA and anti-TB drugs in rabbits.

References:-

1. Askgaard, DS. Wilcke, T. Døssing, M (1995). Hepatotoxicity caused by the combined action of isoniazid and rifampicin. Thorax 50(2):213-4.
2. Aubrecht, J. Schomaker, SJ. Amacher, DE (2013). Emerging hepatotoxicity biomarkers and their potential to improve understanding and management of drug-induced liver injury. Genome Medicine 5:85-7.
3. Burits, M. Bucar, F (2000). Antioxidant activity of Nigella sativa essential oil. Phytother Res 14(5): 323-28.
4. Chaudhary, GD. Kamboj, P. Singh, I. Kalia, AN (2010). Herbs as liver savers- A review. Indian J Nat Prod Resour 1(4): 397-408.
5. Develi, S. Evran, B. Betül Kalaz, E. Koçak-Toker, N. Erata, GÖ (2014). Protective effect of Nigella sativa oil against binge ethanol-induced oxidative stress and liver injury in rats. Chin J Nat Med 12 (7):495-99.
6. El-Dakhkhny, M. Mady, NI. Halim, MA (2000). Nigella sativa L. oil protects against induced hepatotoxicity and improves serum lipid profile in rats. Arzneimittelforschung 50(09):832-36.
7. Eminzade, S. Uras, F. Izzettin, FV(2008). Silymarin protects liver against toxic effects of anti-tuberculosis drugs in experimental animals. Nutr Metab 5(1): 18-26.
8. Hassan, AS. Ahmed, JH. Al-Haroon, SS (2012). A study of the effect of Nigella sativa (Black seeds) in isoniazid (INH)-induced hepatotoxicity in rabbits. Indian J Pharmacol 44(6):678-82.
9. Kanter, M. Coskun, O. Budancamanak, M (2005). Hepatoprotective effects of Nigella sativa L and Urtica dioica L on lipid peroxidation, antioxidant enzyme systems and liver enzymes in carbon tetrachloride-treated rats. World J Gastroenterol 11(42):6684-8.
10. Loots, DT. Wiid, IJ. Page, BJ. Mienie, LJ. van Helden, PD (2005). Melatonin prevents the free radical and MADD metabolic profiles induced by antituberculosis drugs in an animal model. J Pineal Res 38(2):100-6.
11. Schaberg, T. Rebhan, K. Lode, H (1996). Risk factors for side-effects of isoniazid, rifampin and pyrazinamide in patients hospitalized for pulmonary tuberculosis. Eur Respir J 9(10): 2026-30.

12. Shih, TY. Pai, CY. Yang, P. Chang, WL. Wang, NC. Hu, OY (2013). A novel mechanism underlies the hepatotoxicity of pyrazinamide. *Antimicrob Agents Chemother* 57(4):1685-90.
13. Shu, CC. Lee, CH. Lee, MC. Wang, JY. Yu, CJ. Lee, LN (2013). Hepatotoxicity due to first-line anti-tuberculosis drugs: a five-year experience in a Taiwan medical centre. *Int J Tuberc Lung Dis* 17(7):934-9.
14. Sonika, U. Kar P (2012). Tuberculosis and liver disease: management issues. *Trop Gastroenterol* 33(2):102-6.
15. Taneja, DP. Kaur, D (1990). Study on hepatotoxicity and other side effects of antituberculosis drugs. *J Indian Med Assoc* 88(10):278-80.
16. Tostmann, A. Boeree, MJ. Aarnoutse, RE. de Lange, WC. van der Ven, AJ. Dekhuijzen, R (2008). Antituberculosis drug-induced hepatotoxicity: concise up-to-date review. *J Gastroenterol Hepatol* 23(2):192-202.
17. Walubo, A. Smith, PJ. Folb, PI (1995). Oxidative stress during antituberculous therapy in young and elderly patients. *Biomed Environ Sci* 8(2):106-13.