

See discussions, stats, and author profiles for this publication at: <https://www.researchgate.net/publication/325658927>

# ACUTE TOXICOLOGICAL PATHOLOGY OF COUMAPHOS (ORGANOPHOSPHATE COMPOUNDS) IN ROCK DOVE

Article · June 2018

CITATIONS

0

READS

29

1 author:



Qayssar Ali Kraidi

University of Misan

9 PUBLICATIONS 16 CITATIONS

SEE PROFILE

Some of the authors of this publication are also working on these related projects:



ACUTE TOXICOLOGICAL PATHOLOGY OF COUMAPHOS (ORGANOPHOSPHATE COMPOUNDS) IN ROCK DOVE (Columba livia gaddi) [View project](#)

## **ACUTE TOXICOLOGICAL PATHOLOGY OF COUMAPHOS (ORGANOPHOSPHATE COMPOUNDS) IN ROCK DOVE**

*(Columba livia gaddi)*

Qiesar.A.K.

Department of pathology and poultry diseases, college of Veterinary Medicine University of  
Basrah, Basrah, Iraq,.

(Received 17 May 2009, Accepted 13 September 2009 )

**Keywords;** Dove, ALT, Pancrease.

### **ABSTRACT**

The aim of this study was to examine the acute toxicity of organophosphorous insecticide (coumaphos) in wild pigeons (Rock dove) and measure the level of liver enzyme Alanine Transaminase (ALT) in the serum of pigeons treated orally with a single dose 3mg/kg bw. of coumaphos and study the histopathological changes of central and peripheral nervous system, liver, kidney, heart and pancreas after 3 weeks of dosing. The results showed muscarinic, nicotinic and central nervous system effects and as well as showed a significant 5) in the level of ALT in the serum of treated pigeons in comparison with 0 increasing ( $p \leq 0.05$ ) control group. The histopathological results included degeneration of nerve fibers in sciatic nerve, spinal cord and hepatocyte also preportal and septal fibrosis and bile duct proliferation, the kidney showed degeneration of renal tubules and separation of renal capsule

### **INTRODUCTION**

Coumaphos is an organophosphate insecticide compound used against ectoparasites which are insects that live on the bodies of host animals such as sheep, goats, horses, pigs and poultry (1). It can be given orally to adult cattle at 25mg/kg for use as a systemic insecticide without apparent injury (2). It is also used in medicated feed against internal parasites (*Ascaidia galli*, *Capillaria obsignata* and *Heterakis gallinarum*) in layer chickens at concentration of 0.003%-0.004% for 10-14 days repeated in 3 weeks after the previous

treatment (3). Coumaphos is highly toxic to birds (4) severe acute toxicity and eventual death were caused in hens after they were given oral doses of 10mg/kg for 1-8 days, hens given oral doses recovered from initial effects of cholinesterase inhibition and developed signs of delayed nerve poisoning or neurotoxicity (5). The oral LD50 for coumaphos is 3mg/kg in wild birds, 29.4mg/kg in mallard ducks, 7.94mg/kg in pheasants and 14mg/kg in chicken (4).

The aim of this study is to identify the general toxic effect of the test compound on pigeon, also there are few researches dealt with toxicity of organophosphorous in pigeons with the idea of using pigeon as model for toxicity of such insecticide.

## **MATERIALS AND METHODS**

### **-Experimental design**

in Basrah university, the birds were acclimatized for 7 days before start of the experiment.

Primary trials were conducted to determine the maximum tolerated dose by using different doses till reaching 3mg/kg bw of coumaphos. To study the acute toxicity of coumaphos in pigeon sixteen birds were randomly divided into two groups of 8 birds each, birds in group A were dosed orally with 3mg/kg bw of coumaphos dissolved in distilled water and given by oral gavage while birds in group B (control group) were dosed orally distilled water only. Clinical signs were recorded. Twenty days later all birds were killed by decapitation and blood samples were collected and tissue samples from liver, kidney, pancreas, spinal cord, sciatic nerve and brain were taken.

### **-Biochemical estimation**

using Transaminases –kit (Biomerieuxsa® made in France) according to the Reitman and Frankel method (6).

### **Histopathological examination:**

Representative tissue samples were fixed in 10% neutral buffered formalin. After prolonged washing in tap water the sections of tissues were dehydrated in ascending grades of alcohol and then cleared in xylene, paraffin section 5µm thick, were cut and stained with haematoxylin and eosin (7).

### **-Statistical analysis**

Results are expressed as mean ± Standard deviation (SD), difference between mean data according to (SPSS) (8). Differences were considered significant at ( $p \leq 0.05$ ).

## **RESULTS AND DISCUSSION**

### **Clinical sign**

Two birds were died in group A after 20 minute of dosing and before they die exhibited acute toxic symptoms included profuse salivation , recurrent drooping, restlessness, difficult breathing, ataxia, unsteady gait, wing twitching, wing drop and spread wings, tremor, paralysis , recumbent. Other 6 survivor birds in same group exhibited same toxic symptoms in addition to vomiting in 2 birds and slightly salivation in all. same results were recorded in mallard ducks (9).These results were attributed to the mechanism of the toxic actions of organophosphates insecticide in man and animals by inhibition of acetyl cholinesterase at the nerve terminals and this causes acetylcholine accumulation that subsequently causes a series of muscarinic ,nicotinic and central nervous system effect(10,11,12). In this study the sign of un steady gait persisted for 48hour in survivor birds, this result was disagreement with (13)who observed abnormal gait until day 42 after first oral dosing (50mg/kg bw) in Leghorn hens , this result might be attributed to the metabolic variation of species.

### **-Biochemical finding**

5) of ALT values (6.18) in treated OThe results showed significant increased at ( $p \leq 0.05$ ) group compared (3.26) with control group. These finding concurred with earlier report(14)whom observed significant changes of ALT values in broiler chicken fed ration contain chlorpyrifos (organophosphorus insecticide).The increased in ALT values might be attributed to the liver damage in the toxin dosed birds(15).

**Acute toxic effect of coumaphos on ALT value (U/L) in Rock dove after 21days of single dose**

Groups	No. of samples	Mean	S.D.
Treated coumaphos (3mg/kg) A	6	6.18*	±1.83
Control B	6	3.26	±0.43

S.D. =standard deviation

ALT=alanine transaminase,

\*=.means significant in( $p \leq 0.05$ )

**Histopathological examination**

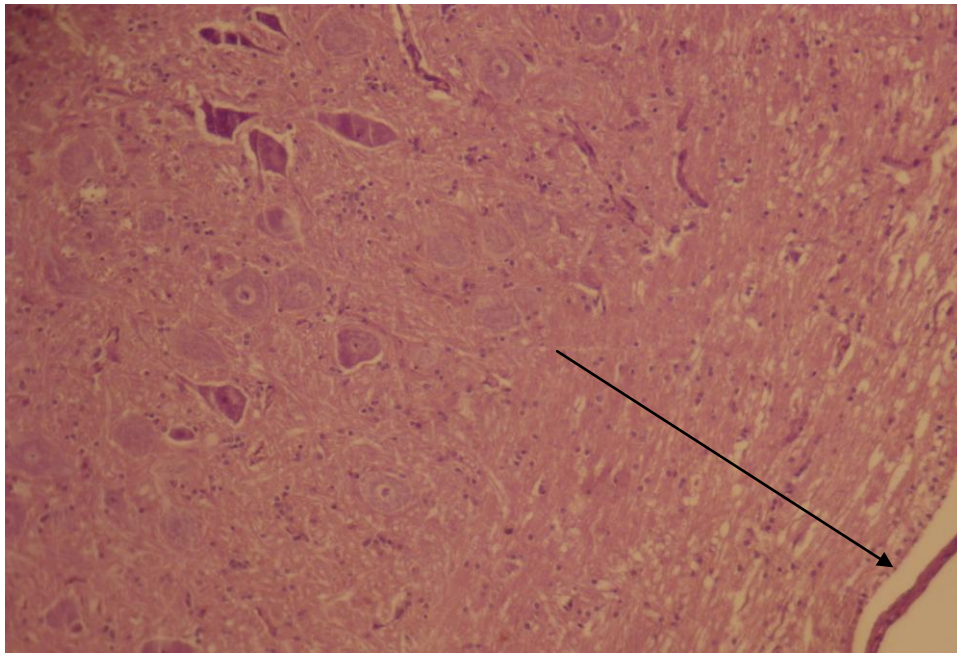
pigeons dosed with 3mg/kg bw of coumaphos per os showed histopathological changes in peripheral nerves (sciatic nerve) and spinal cord ,degeneration in nerve fibers of both ,these results were conflicted with (5,13) which did not report any histopathological changes (degeneration in spinal cord or peripheral nerves) in Leghorn laying hens that received single dose 50 or 100mg/kg bw of coumaphos orally in spite of all hens showed acute cholinergic symptoms, this result might be attributed to the metabolic variation of species. The results in this study did not show histopathological changes in brain and these results were in agreement with (13).

Histopathological changes in liver include preiportal and septal fibrosis with infiltration of inflammatory cells and bile duct proliferation, degeneration of hepatocytes in centrilobular and periportal region and congestion, these results in agreement with (16) who they were referred to the detection of enhanced concentration of enzymes cells liver in the serum blood is indication for damage of the liver parenchyma. Other changes in this study included degeneration of cortical tubules and separation of renal capsule, degeneration of skeletal muscle and the results did not show significant changes in pancreas.

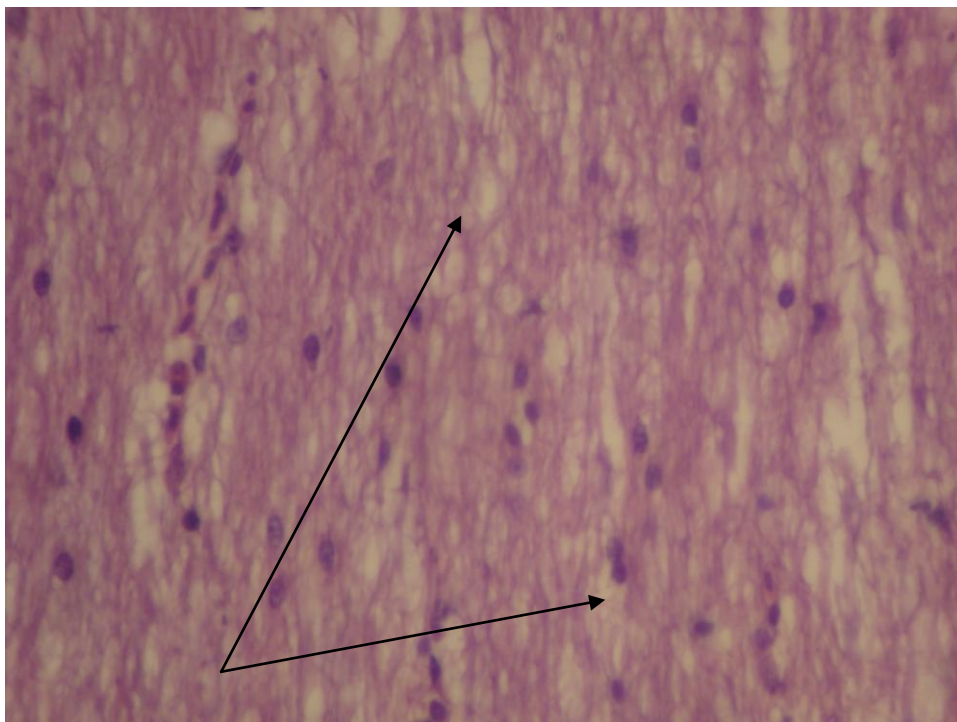
**Conclusion**

Acute exposure of pigeons to cuomaphos associated with concurrent elevation of ALT in serum and with signs of neurotoxicity at maximum tolerated dose in surviving birds and with

histopathological changes in sciatic nerve, spinal cord, liver, kidney and heart. Further researches are needed to study the toxicity of low dose long term exposure to coumaphos.



**Fig (1)** spinal cord show degeneration of nerve fibers in the white matter (x200 H&E)



**Fig (2)** spinal cord show degeneration of the nerve fibers in the white matter ( x 800 H&E)

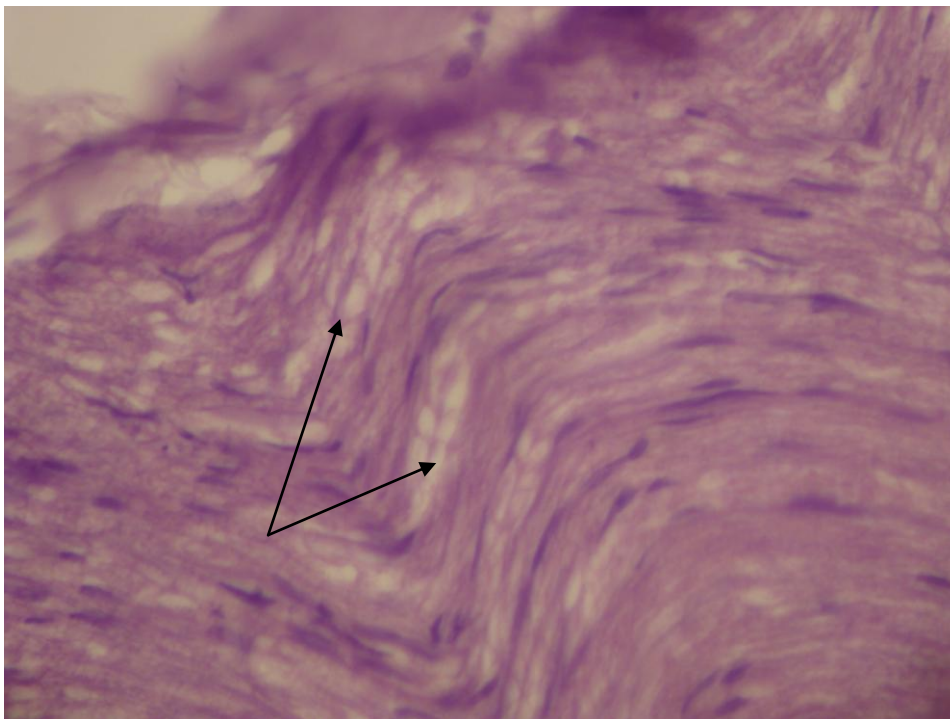


Fig (3) sciatic nerve degeneration on nerve fibers (x800 H&E)

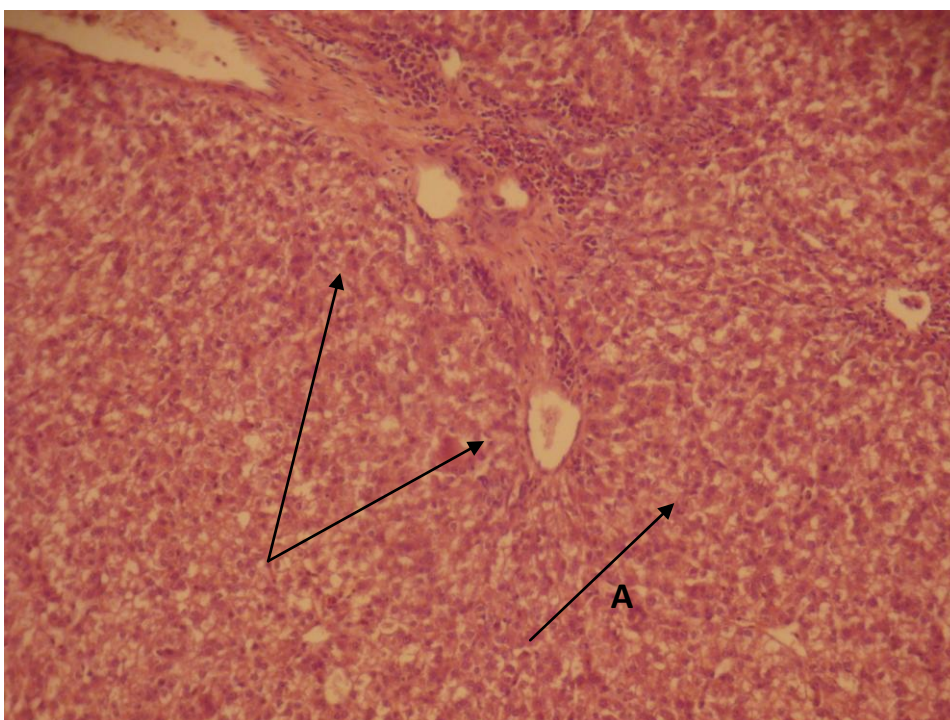
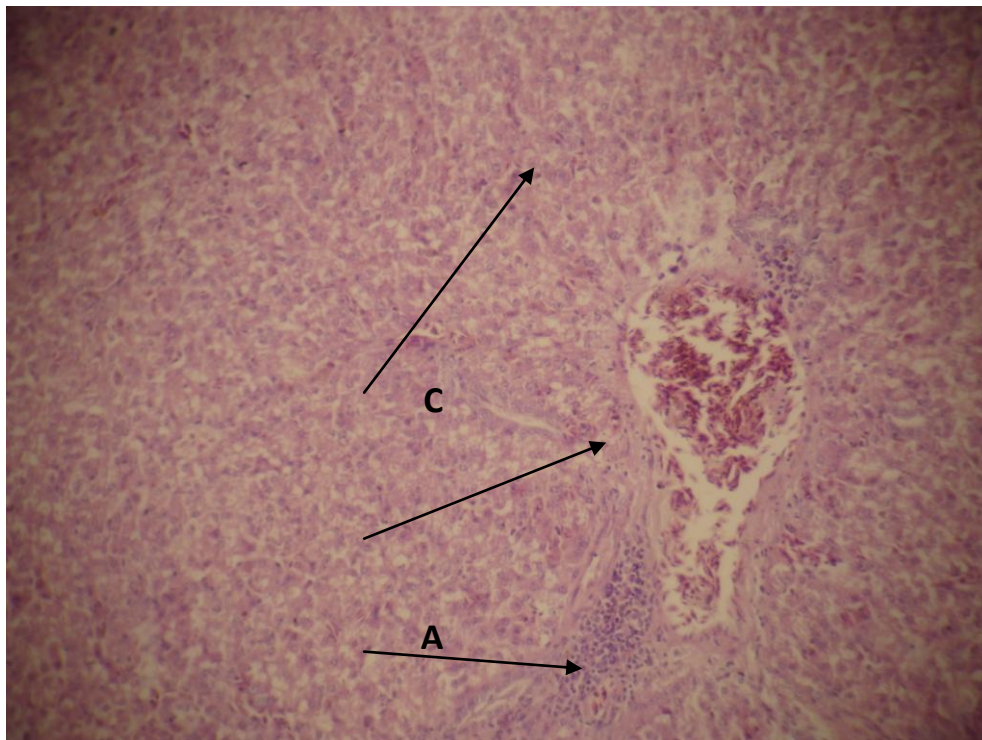


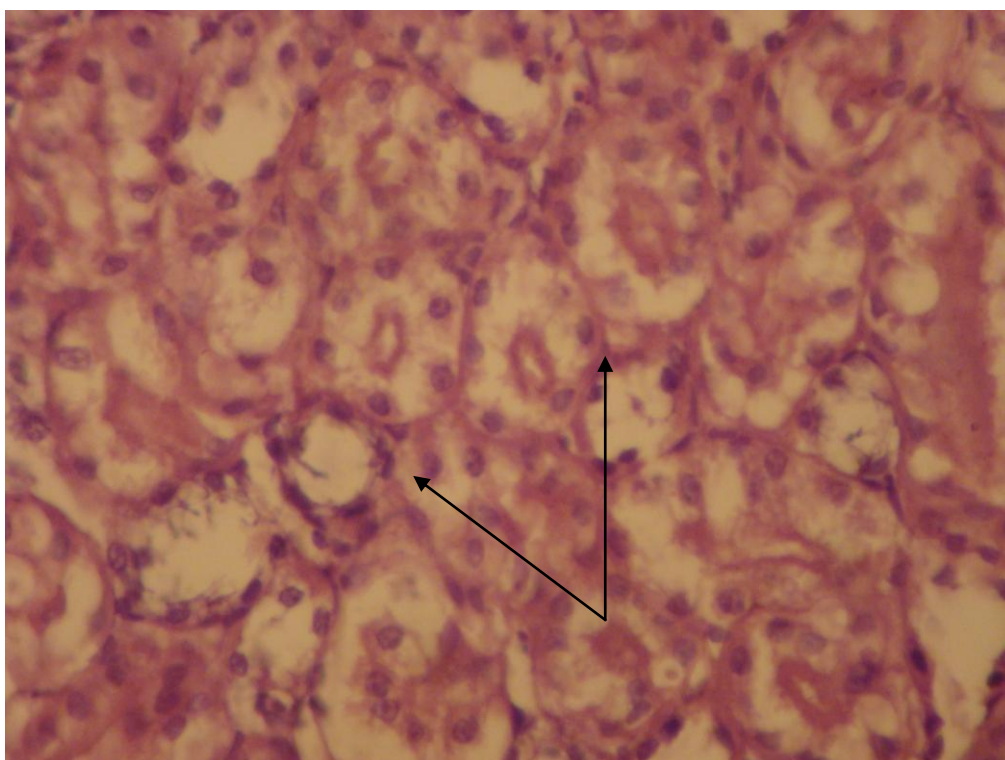
Fig (4) A) liver degeneration of hepatocytes

B) Septal fibrosis (x200 H&E)



**Fig (5) A)** liver congestion of the central vein with fibrosis

**B)** Infiltration of inflammatory cells **C)** degeneration of hepatocyte  
( x200 H&E)



**Fig (6)** degeneration of renal cortical tubules (x800 H&E)



## ACKNOWLEDGEMENT

This Study was supported by the College of Veterinary medicine, University of  
Basrah, Basrah, Iraq.

### التأثير السمي المرضي الحاد لمبيد الكومافوس في الحمام الصخري

قيصر علي كريدي

فرع الأمراض وأمراض الدواجن ، كلية الطب البيطري ، جامعة البصرة ، البصرة ، العراق.

### الخلاصة

كان الهدف من الدراسة هو الكشف عن التأثيرات السمية الحادة للمبيد الفسفوري العضوي الكومافوس في طيور الحمام البرية وقياس مستوى إنزيم الالانين ترانس امينيز في مصل دم الحمام المعامل ب3ملغم/كغم من وزن الجسم عن طريق الفم ودراسة التغيرات النسيجية المرضية في الجهاز العصبي المركزي والمحيطي والكبد والكلية والقلب والبنكرياس بعد ثلاثة أسابيع من المعاملة حيث بينت النتائج ظهور علامات التسمم المسكرينية والنيكوتينية وعلامات التسمم الخاصة بالجهاز العصبي المركزي كما أظهرت النتائج وجود ارتفاع معنوي ( $p \leq 0.05$ ) في مستوى إنزيم الالانين ترانس امينيز في الحمام المعامل بالكومافوس مقارنة مع مجموعة السيطرة ، التغيرات النسيجية المرضية تضمنت تنكس خلايا الألياف العصبية للعصب الوركي والحبل الشوكي ، تنكس الخلايا الكبدية وتليف المنطقة البوابية مع تليف حويجزي ، تنكس النيبات القشرية للكلية وانفصال المحفظة الكلوية.

## REFERENCES

- 1-U. S. Environmental Protection Agency. 1985 (Oct. 31). EPA chemical profile: coumaphos. Washington, DC
- 2-Clarke, E.G.C. and Clarke, M.L.(1975).Veterinary toxicology .Published in the United States of America by the Williams and Company, Baltimore.
- 3-Calnek,B.W.;Barnes,H.J.;Beard,C.W.;Mcdougald,L.R.and Saif,Y.M.(1997).Diseases of poultry.10<sup>th</sup> edition,Mosb-Wolfe,Iowa state University press,Ames.
- 4-U.S. Environmental Protection Agency. (1989) Pesticide Fact Sheet: Coumaphos (Fact Sheet Number 207). US EPA, Washington, DC.

- 5-Abou-Donia,M.B.;Makkawy,H.and Graham, D.J.(1982).Coumaphos :delayed neurotoxic effect following dermal administration in hens.J.Toxicol. Environ. Health. 10:87-99.
- 6-Reitman S. and Frankel S.(1975)Am. J.clinic.path.28,65
- 7-Luna, L..G.(1968).Munal of histological staining method of the armed institute of pathology .3<sup>rd</sup> edition .MC Graw .Hill book .co.London.
- 8-SPSS(1998).Version 11.Statistical Packages of Social Science.USA.
- 9-Tucker, R. and D. G. Crabtree. (1970). Handbook of toxicity of pesticides to wildlife. U. S. Department of Agriculture, Fish and Wildlife Service. Bureau of Sport Fisheries and Wildlife. Washington, DC: U.S. Government Printing Office.
- 10-Bajgar J.(2004).Organophosphates/nerve agent poisoning:mechanism of action,diagnosis,prophylaxis and treatment.Adv.clin.chem.38:151-216.
- 11-Kwong TC.(2002).Organophosphate pesticides biochemistry and clinical toxicology. Ther.Drug.monit.24:144-149.
- 12-Rusyniak ,DE .and NanagasK. A. (2004) .Organophosphate poisoning .Semin .Neurol.24:197-204.
- 13-Flucke, W., Kaliner, G. Asuntol-Wirkstoff(1987). An examination of acute neurotoxicity after oral dosing in the hen. Unpublished report NO. 15430 from Bayer AG, Institute of Tootoxicology. Submitted to WHO by Bayer.
- 14-Yadav,S.S,Mukhopadhyay and K.Purohit,(2003) Eperimentally induced chlopyriphos toxicity in broiler: haematobiochemical and pharmacological studies in 20<sup>th</sup> Annual Conference of Indian Association of Veterinary Pathologists.3:103.
- 15-P.Krishnamoorthy,S.Vairamuthu,C.Balachandranand B. Muralimanohor . (2006). Chloryripyriphos and T-2 Induced Haemato-Biochemical Alterations in broiler Chicken.Inter.J.of Poult.Sci.,Vol.5(2):173-177.
- 16-Herna, A.; Del Razo, L.M.;Gonzalo, C.A.; Borja,V.H. and Arnulfo,M.A.(1999).Altered activity of heme biosynthesis pathway enzymes in individual chronically exposed to arsenic in mexico.Arch. Toxicol.,Vol.73(2),90-95.