

See discussions, stats, and author profiles for this publication at: <https://www.researchgate.net/publication/330093397>

THE POSSIBLE PROTECTIVE EFFECTS OF CANDESARTAN AGAINST METHOTREXATE INDUCED HEPATOTOXICITY IN RABBITS

Article in *Pharmacologyonline* · December 2018

CITATIONS

0

READS

130

2 authors, including:



Rasha Kareem

University of Misan

6 PUBLICATIONS 0 CITATIONS

[SEE PROFILE](#)

Some of the authors of this publication are also working on these related projects:



Methotrexate Hepatotoxicity [View project](#)



A study of the effect of Nigella sativa (Black seeds) on pyrazinamide and anti-tuberculosis drugs induced hepatotoxicity in rabbits [View project](#)

THE POSSIBLE PROTECTIVE EFFECTS OF CANDESARTAN AGAINST METHOTREXATE INDUCED HEPATOTOXICITY IN RABBITS

Tahssein Ali Mohammed¹; Rasha Kareem Khudur²; Ali Abdulaziz Alshawi³; Adeb A. Al-Zubaidy¹

¹Al-Nahrain University, Baghdad, Iraq

²Missan University, Missan, Iraq

Email address: rashapharma87@gmail.com

Abstract

Methotrexate (MTX) is a folic acid antagonist that is widely used as a cytotoxic chemotherapeutic agent for treatment of leukemia and other malignancies and as anti-inflammatory and immunosuppressive agent in non-neoplastic diseases such as psoriasis, arthritis and SLE. MTX and its poly glutamated metabolite (7-OH-MTX) stored in hepatocytes for long period causes oxidative stress and lipid peroxidation in liver and renal tissue by increase the generation of reactive oxygen and nitrogen species. Candesartan Cilexetil (CC) is an orally active and selective angiotensin II (Ang II) type one receptor blocker with anti-inflammatory and antioxidant effect and it is widely used for the treatment of hypertension and heart failure. This study was designed to evaluate the possible protective effects of candesartan cilexetil against methotrexate induced hepatotoxicity in rabbits. The animal groups were divided into five groups involve control group, Methotrexate induction groups received 20mg/kg and 100 mg /kg a single intra-peritoneal dose at day 4 to induced hepatotoxicity. These groups served as positive control of liver damage. Candesartan + Methotrexate groups (pre and post group) in which rabbits treated with Candesartan 10 mg /kg orally for 10 days with MTX 20mg/kg and or 100 mg/kg a single dose intra-peritoneal at day 4. The animals were sacrificed on day 10. then estimation of serum levels of (AST), (ALT) and (ALP). Also the liver tissue homogenate was prepared to evaluate tissue levels of malondialdehyde (MDA) and glutathione (GSH). Finally, liver tissue sections were prepared by using paraffin sections technique and stained with hematoxylin and eosin for histological evaluation.

Keywords: Methotrexate (MTX); Hepatotoxicity; Candesartan Cilexetil (CC); Rabbits

Introduction

Cancer chemotherapy remains an intriguing area of pharmacology. On one hand, the use of anticancer drugs produces high rates of cure of the disease in which without chemotherapy, result in extremely high mortality rates. On the other hand, some types of cancer are barely affected by currently available drugs¹. Methotrexate (MTX) is an anti-metabolite anti foliate chemotherapeutic agent that introduced for therapeutic application in the 1950s. It is commonly prescribed for various cancers and autoimmune diseases that is widely used as a cytotoxic chemotherapeutic agent for treatment of leukemia and other malignancies and as anti-inflammatory and immunosuppressive agent in non-neoplastic diseases such as psoriasis, arthritis and SLE². In the liver the conversion of MTX to its major extracellular metabolite (7-hydroxy MTX) occurred where it is oxidized by a soluble enzymatic system. Inside hepatocytes MTX is stored in a poly glutamated form in which long term drug administration can cause accumulation of MTX poly glutamates causes a longer intracellular presence of the drug and decreased foliate levels result in de novo inhibition of purine and pyrimidine synthesis leads to DNA, RNA defects which results in apoptosis this has been suggested as a mechanism for MTX hepatotoxicity^{3,4}. Moreover, MTX causes oxidative stress and lipid peroxidation in liver tissue by increase the generation of reactive oxygen and nitrogen species like nitric oxide (NO[·]) an inorganic free radical gas produced from L-arginine by nitric oxide synthase (NOS) appears to be intimately involved in super oxide mediated tissue injury⁵. The concurrent production of mitochondrial superoxide and cytoplasmic (NO[·]) leads to the rapid formation of peroxy nitrites (ONOO⁻)⁶; the major toxic product leading to much of the damage through oxidation of cellular structures including DNA and causes lipid peroxidation that increased activities of malondialdehyde (MDA)^{7,8}. Candesartan Cilexetil (CC) is an orally active and selective angiotensin II (Ang II) type one receptor blocker and it is widely used for the treatment of hypertension and heart failure⁹. Ang II is the main effector molecule of the rennin-angiotensin system (RAS) in which its binding to the AT₁ receptor leads to activation of several classic second messenger systems that induce the

following actions¹⁰ (Pro-oxidative effects of Ang II and Aldosterone, Pro-inflammatory and Pro-fibrogenic actions, Ang II induce vasoconstrictor effect, Stimulation of cell proliferation).

Methods

Thirty domestic rabbits of both sexes, weighing 1.5-2 kg were used in this study will be randomly divided into five groups each of six animals. The animals were fed commercial pellets and tap water. Groups of animals utilized in this study were kept in separate cages. The experimental protocol for this study are: Group I: (control group) apparent healthy rabbits were received tap water and the animals were anesthetized by ether and then were sacrificed on day 10. Group II-A: (First induction group) rabbits received at day 4 a single intra-parenteral dose of MTX (20mg/kg i.p) in order to induce hepatotoxicity. These animals were anesthetized by ether and then were sacrificed on day 10. This group served as first positive control of liver damage. Group II-B: (First treatment group) in which rabbits received a single daily dose of candesartan (10mg/kg) orally for 10 days (pre and post) and received at day 4 a single dose of MTX (20mg / kg i.p) . These animals were anesthetized by ether and then were sacrificed on day 10. Group III-A: (Second induction group) rabbits received at day 4 a single dose of MTX (100mg/kg i.p) in order to induce hepatotoxicity. These animals were anesthetized by ether and then were sacrificed on day 10. This group served as second positive control of liver damage. Group III-B: (Second treatment group) in which rabbits received a single daily dose of candesartan 10 mg/kg orally for 10 days (pre and post) and received at day 4 a single dose of MTX (100 mg/kg i.p). These animals were anesthetized by ether and then were sacrificed on day 10.

Before the animals have been anesthetized by ether, the blood was collected by intra-cardiac puncture then centrifuged at 3000 rpm for 15 minute the supernatant was used for the estimation of serum levels of (AST, ALT and ALP) . Also the liver tissue homogenate will be prepared to evaluate tissue levels of malon-dialdehyde (MDA) and glutathione (GSH).

Finally, liver tissue sections were prepared according to the method of Junqueira et al in 1995 by using paraffin sections technique and stained with

hematoxylin and eosin for histological evaluation¹¹. The liver damage severity was semi-quantitatively assessed were based on intensity and diffusion of degeneration in hepatocytes, hepatocytes with eosinophilic cytoplasm, hydropic degeneration (cytoplasmic vacuolization and swelling of hepatocyte), proliferation in bile duct, inflammation in portal space and parenchymal necrosis. At the end, Microscopic damage was identified in accordance to the scoring¹²; as follows: [(0): normal, (1):mild, (2): moderate, (3): sever ,(4): very sever] for each criterion.

Results

1. *Effects of oral candesartan (10mg/kg/day) for 10 days on the serum levels of aspartate aminotransferase (AST), alanine aminotransferase (ALT) and alkaline phosphatase (ALP) against methotexate (MTX) induced hepatotoxicity in rabbits:*

Data of all groups are expressed as (Mean \pm SEM), in group IIA (GP-IIA) rabbits treated with a single dose of MTX (20mg/kg) showed a significant increase in the serum levels of AST, ALT and ALP [(69.82 \pm 5.5), (105.9 \pm 2.25), (64.23 \pm 2.69)] respectively compared to control group (GP-I) [(28.86 \pm 3.97), (68.63 \pm 4.39), (40.37 \pm 2.24)] (P<0.05). While in group IIB (GP-IIB) rabbits treated with oral candesartan (10mg/kg/day) for 10 days prior to and during intra-peritoneal administration of MTX (20mg/kg) produced a significant reduction in the serum levels of AST, ALT and ALP [(43.01 \pm 6.11), (81.19 \pm 3.8), (46.1 \pm 3.32)] respectively compared to that observed in group-IIA (GP-IIA) (p<0.05) But all showed non-significant difference compared to control group (p>0.05) (GP-I). Table (1), Figures: (1,2,3).

Also in group IIIA (GP-IIIA) rabbits treated with a single intra-peritoneal dose of MTX (100mg/kg) showed asignificant elevation in the serum levels of AST, ALT and ALP [(83.96 \pm 5.81),(111.5 \pm 4.09),(88.22 \pm 3.85)] respectively compared to control group (GP-I) [(28.86 \pm 3.97), (68.63 \pm 4.39), (40.37 \pm 2.24)] (P<0.05). While in group IIIB (GP-IIIB) rabbits received oral candesartan (10mg/kg/day) for 10 days prior to and during intra-peritoneal administration of MTX (100mg/kg) produced a significant reduction in the serum levels of AST, ALT and ALP [(36.95 \pm 2.48), (72.44 \pm 5.14),

(45.82 \pm 2.79)] respectively compared to that observed in group-IIIA (GP-IIIA) (p< 0.05), but all showed non-significant difference compared to control group (GP-I) (p>0.05), Table (1), Figures: (1,2,3). Finally there is a significant elevation in the serum levels of (AST, ALT and ALP) between the two induction groups (GP-IIA and GP-IIIA).

2. *Effects of oral candesartan (10mg/kg/day) for 10 days on the Lipid Peroxidation (MDA) Levels and Glutathione (GSH) Levels against methotexate (MTX) induced hepatotoxicity in rabbits:*

Group IIA (GP-IIA) rabbits treated with a single intra-peritoneal dose of MTX (20mg/kg) showed a significant elevation in the levels of lipid peroxidation end product (MDA) (52.47 \pm 3.55) with a significant reduction in the levels of glutathione(GSH) (6.53 \pm 2.25) in liver tissue homogenate compared to control group (GP-I) [MDA(26.49 \pm 2.26), GSH(24.04 \pm 2.1)] (p<0.05). While in group IIB (GP-IIB) rabbits received oral dose of candesartan (10mg/kg/day) for 10 days prior to and during intra-peritoneal administration of MTX (20mg/kg) produced a significant reduction in (MDA) levels (34.39 \pm 3.26) and a significant elevation in (GSH) levels (19.02 \pm 1.88) in liver tissue homogenate (p<0.05) compared to that observed in group IIA (GP-IIA), these values showed non-significant difference compared to control group (GP-I) (p>0.05). Table (1), Figures: (4, 5).

Group IIIA (GP-IIIA) rabbits treated with a single intra-peritoneal dose of MTX (100mg/kg) showed a significant elevation in the levels of MDA (61.72 \pm 5.53) and a significant depletion in the levels of GSH (4.37 \pm 0.91) in liver tissue homogenate compared to control group (GP-I) [MDA (26.49 \pm 2.26), GSH(24.04 \pm 2.1)] (p<0.05), While in Group IIIB (GP-IIIB) rabbits treated with oral candesartan (10mg/kg/day) for 10 days prior to and during intra-peritoneal administration of MTX (100mg/kg) produced a significant reduction in MDA levels (28.46 \pm 2.98) and a marked significant elevation in GSH levels (20.69 \pm 1.36) in liver tissue

homogenate at (p<0.05) compared to that observed in group IIIA (GP-IIIA), these values showed non-significant difference compared to control group (GP-I) (p>0.05). Table (1), Figures: (4,5). Finally, there

is a significant elevation in the levels of (MDA) and a significant reduction in the levels of (GSH) between the two induction groups (GP-IIA and GP-IIIA).

3. Histopathological Changes of Liver Tissues:

The mean of histopathological scores for rabbits treated with a single dose of MTX (20mg/kg i.p.) in liver tissue of group (GP-IIA) showed a moderate score level [score number (3)] that include scattered hepatocyte, moderate hydropic degeneration with obvious piecemeal necrosis, bile duct proliferation and inflammatory portal cells infiltration around portal area and it is found to be significantly increased compared to control group (GP-I) ($p < 0.05$). Table (2), Figures: (1,2).

In (GP-IIB) rabbits treated with oral candesartan (10mg/kg/day) for 10 days prior to and during intra-peritoneal administration of MTX (20mg/kg) showed a mild score level [score number (2)] of histopathological changes that involve dis-appearance of hydropic degeneration with mild traditis and no bile duct proliferation which significantly decreased in comparison with (GP-IIA) ($p < 0.05$) and non-significant changes compared to control group (GP-I). Table (2), Figure (3).

The mean of histopathological scores in group III-A (GP-IIIA) for rabbits treated with a single dose of MTX (100mg/kg i.p.) showed severe to very severe score level that include severe hydropic degeneration of hepatocyte with feathery cytoplasm and port portal bridging with scattered hepatocytic vaculation [score number-4], loss of architecture with piecemeal hepatocyte necrosis and nuclear fragmentation (karyorrhexis) and both are significantly increased in comparison to both (GP-I and GP-IIA) ($p < 0.05$), these histo-pathological changes are showed in table (2). Figure (4).

In group IIIB (GP-IIIB) the mean of score level for rabbits received oral candesartan (10mg/kg/day) for 10 days prior to and during intra-peritoneal administration of MTX (100mg/kg) showed mild hydropic degeneration with less feathery changes [score number (2); Figure(5) and it is significantly decreased compared to (GP-IIIA) ($p < 0.05$) and non-significantly different compared to control group (GP-I) At the end; there was a significant increased between score means of (GP-IIA and GP-IIIA) ($p < 0.05$).Table (2).

Discussion

Antitumor drugs are being increasingly utilized for patients at high risk for recurrent disease⁽¹⁴⁾. Further drugs used for cancer chemotherapy are well known to produce side effects in multiple organ systems the most common target organs are tissues that contain self-renewing cell populations such as gastrointestinal tract, bone marrow, kidney, mucosal membranes, and hair follicles⁽¹⁵⁾.

MTX a folic acid antagonist is widely used anti-metabolite cancer chemotherapy and in many diseases like rheumatologic, dermatologic, and hematologic successfully. It is known to have the major toxic effects due to oxidative reactions that take place during its metabolism in the liver^(16,17). There is substantial evidence for a role of reactive oxygen metabolites in mediating hepatic and renal toxicity of some xenobiotics and the pathogenesis of organ failure⁽¹⁸⁾. A previous study showed that oxygen free radicals and hydrogen peroxides are linked with the development of several pathological processes associated with chemotherapy⁽¹⁹⁾.The severity of methotrexate associated liver and renal injuries is related to both the dose and duration of the treatment⁽²⁰⁾.

In the present study; it has been shown that a single (i.p.) dose of MTX 20mg/kg in (GP-IIA) caused toxic effects on the liver provoking a significant notable elevation in the serum levels of AST, ALT compared to control group (GP-I).These enzymes are liver specific and present in cytoplasm of hepatocyte and are involved in the breakdown of amino acids into a keto acid which is routed for complete metabolism through the Krebs cycle and electron transport chain⁽²¹⁾.The increment in these enzymes levels reflected impaired liver function which indicate leakage in plasma membrane permeability resulting in leakage of large quantities of enzymes into the blood stream which is often associated with cell death, massive damage or necrosis of hepatocytes⁽²²⁾.

This elevation in serum hepatic enzymes indicated deterioration in hepatic function due to parenchymal injury after MTX administration and this is in harmony with previous reports^(23,24).

Also in the present study, a single (i.p.) dose of MTX 20mg/kg significantly raised serum level of ALP compared to control group(GP-I). This indicated

significant damage to the body tissues by MTX resulting in liberation of ALP in serum⁽²⁵⁾ and this increment was observed with the cholestatic features which is a form of liver injury that results from either decrease in the volume of bile formed or an impaired secretion of specific solutes into bile and it is characterized biochemically by a sharp elevation in serum activities of enzymes localized into bile ducts particularly alkaline phosphatase (ALP). In addition to the elevation of serum levels of bile salts due to defect in liver secretion ability, so that ALP is used as indicator for assessment of hepatic excretory action⁽²⁶⁾.

Oxidative stress or oxidative cellular damage with its dual of free radical generation and profound lipid peroxidation are hallmarks of acute methotrexate toxicity and also it has been implicated as a common link between chronic liver damage and hepatic fibrosis⁽²⁷⁾. Since reactive oxygen molecules (ROS) mainly originate from many inflammatory cells such as neutrophils and macrophages; these species lead to cellular damage by peroxidation of membrane lipids, sulfhydryl enzyme inactivation, protein cross-linking and DNA breakdown and it could be concluded that these cells might also have an impact in MTX-induced cellular toxicity⁽²⁸⁾.

In the present study, it has been shown that a single (i.p.) dose of MTX 20 mg/kg caused toxic effects on the liver that was suitable for studying the oxidative injury. This dose altered the oxidant /antioxidant balance that is significantly increases the level of lipid peroxidation (MDA) in the liver, these changes result from accumulation of MTX poly glutamates (7-OH MTX) causes a longer intracellular presence of the drug in the hepatic tissues and decreased foliate levels via inhibition of Di-hydro foliate reductase enzyme (DHFR) result in de novo inhibition of purine and pyrimidine synthesis leads to DNA, RNA defects which results in apoptosis this has been suggested as a mechanism for MTX hepatotoxicity^(29,30).

In addition to several reports demonstrating that MTX produce high levels of (ROS) lead to increased lipid peroxidation, modulation of intracellular oxidized states, DNA and cell membrane damage, altered gene expression and apoptosis in different body tissues. In fact a relationship between ROS and apoptosis has been established by many experimental findings and studies have reported that

antioxidants can suppress or delay apoptosis by acting as scavengers of ROS in different systems^(31,32).

It was reported that under normal condition glutathione (GSH) could have a role in maintaining activity of the pentose phosphate cycle at a level which is appropriate for the severity of the oxidative challenge as well as for the capacity of the cellular antioxidant defenses⁽³³⁾, which in its reduced form (reduced GSH) is necessary for the detoxification of xenobiotics; so that a decline in the constitutive GSH levels and capacity for GSH synthesis adversely affects cellular thiol-redox balance and potentially sensitize the cells and made them susceptible to a number of internal and environmental stresses⁽³⁴⁾. As a result this dose of MTX caused a significant decreases in GSH levels in liver. The reduction in GSH levels promoted by MTX represents an alteration in the cellular redox state in which under normal conditions NADPH is used by glutathione reductase enzyme (GSH reductase) to maintain the reduced state of cellular glutathione an important cytosolic antioxidant, previous study demonstrated that the cytosolic nicotinamide adenosine di-phosphate (NADP) dependent dehydrogenases and NADP malic enzyme are inhibited by MTX suggesting that the drug could decrease the availability of NADPH (nicotin amide adenosine diphosphate hydrogen) in cells that lead to inhibition of glutathione reductase (GSH reductase) activity and finally an inhibition of GSH cycle⁽³⁵⁾. Other reports explained this reduction in GSH level might be due to the increased utilization of the hepatocytes in scavenging toxic free radicals of MTX. It has been reported that most covalent binding of toxicant to hepatic protein occurs only after depletion of GSH and the severity of hepatic necrosis was related to the degree of covalent binding, thus lead to the cells could be more sensitive to reactive oxygen metabolites and leads to a reduction of effectiveness of the antioxidant enzyme defense system^(36,37). On the other hand, Rouse et al. suggested that intravenous glutamine protects liver cells from methotrexate induced oxidant injury by increasing intracellular GSH metabolism⁽³⁸⁾. In the present study administration of oral candesartan (10mg/kg/day) for 10 days prior to and during parenteral administered (MTX 20mg/kg) to the rabbits in group IIB significantly prevented AST and ALT elevation and Improved liver functions. In this

view the reduction in the serum levels of AST and ALT which may be a consequence of plasma membrane regeneration and indicates of the ability of candesartan for stabilizing plasma membrane as well as the repair of hepatic tissue damage caused by MTX induced oxidative stress via ROS, this effect is agreeable with the commonly accepted view in which serum levels of transaminase return to normal with the healing of hepatic parenchyma and regeneration of hepatocytes and this suggested that candesartan may have direct effect on fibrosis rather than indirect effect mediated by hepatoprotection⁽³⁹⁾.

Furthermore, the ability of candesartan for reducing the serum level of ALP could be explained by reducing the noticeable damage that induced by MTX that affected the endothelial cells lining the blood sinusoids and blood vessels in the portal tracts which are considered to be the main sites at which the ALP acts and suggests the stability of the biliary dysfunction in rabbit liver during injury induced by MTX⁽⁴⁰⁾.

In group (GP-IIB) candesartan anti-oxidative effect significantly decreased lipid peroxidation level (MDA) and increased glutathione level (GSH) in the liver tissues compared with MTX (20 mg/kg) treated animals suggesting the antioxidant and free radical scavenging activity of candesartan may reduce the toxic effects of MTX. The antioxidant and anti-inflammatory effect of candesartan was attributed to blockade of angiotensin receptor and inhibition of Ang-II induced generation of ROS via activation of (NADPH-oxidase) enzyme which is a major source of ROS and oxidative stress in different tissues that mediates tissue damage^(41,42). Other explanation include candesartan attenuated tissue damage by suppressing transforming growth factor- β 1(TGF- β 1) mRNA and decreasing production of extracellular matrix proteins that is similar to anti-oxidant effects of candesartan were reported by previous study⁽⁴³⁾.

In the present study the inductive dose of MTX (20mg/kg) was not sufficient to induce renal damage at this short period of time and not produced significant changes in renal tissues because of MTX is an acidic compound that its highly eliminated in alkaline urine of rabbits so that it not precipitated in renal tubules and cause toxic damage at low doses⁽⁴⁴⁾. So that different replicated doses of MTX were gradually selected (40mg/kg, 60mg/kg, 80mg/kg and

100mg/kg) and were done a pilot study of two animals for each dose to detect the degree of tissue damage in the hepatic and renal tissues. After that the mean of each biochemical parameter for each selected dose was calculated and compared them with the mean of control group (GP-I), then found that both doses of MTX (40mg/kg, 60mg/kg) caused a significant elevation in serum levels of AST, ALT, ALP and non-significant changes in serum levels of urea, creatinine, TSP and albumin. While the dose of MTX (80mg/kg) produced a significant elevation in serum levels of AST, ALT, ALP and a mild significant elevation in serum levels of urea, creatinine, TSP and albumin⁽⁴⁴⁾.

In the present study, it has been shown that a single (i.p.) dose of MTX 100mg/kg in (GP-IIIA) produced toxic effects on the liver tissue apparently as notable as significant elevation in the serum levels of AST, ALT and ALP compared to control group. The elevation in the level of these enzymes reflect impaired liver function which is previously explained at the dose of MTX (20mg/kg)⁽²²⁻²⁵⁾.

Also in this group (GP-IIIA), this dose of MTX has been altered the oxidant/antioxidant balance and produced oxidative tissue damage in the liver of rabbits that caused significant elevation in the levels of lipid per-oxidation end product (MDA) in liver tissue homogenate compared to control group (GP-I). Several reports demonstrating that methotrexate induces oxidative stress in the liver tissue^(31,32), this change in MDA level was previously explained at the dose of MTX (20mg/kg).

As we previously explained glutathione (GSH) in its reduced form is an important cytosolic antioxidant that is necessary for the detoxification of xenobiotics that caused cellular oxidative damage^(33,34) So that in group-IIIA rabbits received a single (i.p.) dose of MTX(100mg/kg) showed a significant depletion in the levels of GSH in liver. For the same reasons that explained in the inductive toxic dose of MTX (20mg/kg) the significant reduction in GSH levels promoted by methotrexate at this dose (100mg/kg) represents an alteration in the cellular redox state that caused inhibition of glutathione reductase activity and finally an inhibition of GSH cycle⁽³⁵⁾, this lead to the cells could be more sensitive to reactive oxygen metabolites and leads to a reduction of effectiveness of the antioxidant enzyme defense system^(36,37).

In the present study, in group-IIIB rabbits treated with oral candesartan (10mg/kg/day) for 10 days prior to and during (i.p.) administration of MTX (100mg/kg) produced a significant reduction in the serum levels of AST, ALT, ALP and improved liver functions; this reduction in the serum levels of liver enzymes reflecting the ability of candesartan for stabilizing plasma membrane as well as repair of hepatic tissue damage caused by oxidative stress and the reasons for that are previously explained in group-IIIB.

Also in this group (GP-IIIB) the effect of candesartan in hepatic tissues provoked a significant reduction in the levels of lipid peroxidation end product (MDA) and a significant elevation in the levels of glutathione (GSH) in compared with methotrexate treated animals (GP-IIIA) , these events are briefly discussed in group-IIIB. Finally, the biochemical changes induced by MTX treatment were confirmed histopathologically⁽⁴⁵⁾. In which the effects of MTX on the liver of rabbits that received (20mg/kg) in group IIA showed cytoplasmic vacuolation of the hepatocyte with moderate hydropic degeneration and obvious piece meal necrosis with bile duct proliferation. While the histopathological changes in rabbits received a single (i.p.) of MTX (100mg/kg) in group IIIA showed severe hydropic degeneration with hepatocyte hydropic feathery and port portal bridging with scattered hepatocytic vacuolation and loss of architecture with piece meal hepatocyte necrosis and nuclear fragmentation (karyhexis).

These histopathological findings in liver are in agreement with the biochemical findings like increased levels of AST, ALT and ALP in which MTX has a direct participation in liver structures alterations and causes the cytotoxicity of hepatocytes with vacuolation of hepatic cytoplasm . These changes in the hepatic tissues might be due to hypoxia as a result of anemia which causes moderate to severe reversible changes in parenchymatous organs are in agreement with previous studies^(26,46).

Rabbits treated with oral candesartan (10mg/kg/day) for 10 days prior to and during (i.p.) administration of MTX (20mg/kg) in group-IIIB showed disappearance of hydropic degeneration with mild traditis with normal bile duct. While in group IIIB, showed mild hydropic degeneration with less feathery changes. These histopathological

findings in liver is in agreement with the biochemical findings like reduced serum levels of AST, ALT and ALP. These changes occurred firstly due to blockade of angiotensin receptor by candesartan that cause inhibition of Ang-II induced generation of ROS via activation of NADPH-oxidase which is a major source of ROS and oxidative stress in different tissues that mediates tissue damage^(41,42). Secondly candesartan attenuated tissue damage by suppressing transforming growth factor- β 1(TGF- β 1) mRNA and decreasing production of extracellular matrix proteins⁽⁴³⁾.

Referances

1. Trevor, AJ; Katzung, B.G. and Masters, S.B. Cancer Chemotherapy. In Pharmacology examination and board review. Trevor, AJ; Katzung, B.G. and Masters S.B (eds.) 9th edition. International edition McGraw-Hill. 2010; p: 469-481.
2. Widemann, B.C.; Balis, F.M.; Kempf-Bielack, B.; Bielack ,S.; Ferrari, S. and Bacci ,G, Craft ,A.W. and Adamson ,P.C.. High-dose methotrexate-induced nephrotoxicity in patients with osteosarcoma: incidence, treatment, and outcome. *Cancer*. 2004; 100, p: 2222-2232
3. Sotoudehmanesh, R; Anvari, B; Akhlaghi, M. et al. Methotrexate Hepatotoxicity in Patients with Rheumatoid Arthritis. *Middle East J. Digest. Disease*. 2010; 2, P: 104-109.
4. Johovic, N., Cevik, H., Sehirli, O. A., Yegen, B. C, and S, ener, G. Melatonin prevents methotrexate-induced hepato-renal oxidative injury in rats. *Journal of Pineal Research* . 2003. 34, P: 282–287.
5. Walker, LM; Walker, PD; Imam, SZ; Ali, SF and Mayeux, PR: Evidence for peroxynitrite formation in renal ischemia reperfusion injury: studies with the inducible nitric oxide synthase inhibitor L-N(6)-(1-iminoethyl) lysine. *J Pharmacol Exp Ther*. 2000; 295 , P: 417–422.
6. Ozyurt, H; Irmak, MK; Akyol, O and Sogut, S: Caffeic acid phenethyl Ester changes the indices of oxidative

stress in serum of rats with renal ischemia-reperfusion injury. *Cell Biochem Funct.*2001; 19, P: 259–263.

7. Ozen, S.; Akyol, O; Iraz, M.; Sogut, S.; Ozugurlu, F.; Ozyurt, H.; Ersan OE and Yildirim, Z: Role of caffeic acid phenethyl ester, an active component of propolis, against cisplatin-induced nephrotoxicity in rats. *J Appl Toxicol* .2004; 24, P: 27–35.

8. Sogut, S.; Zoroglu, S.S.; Ozyurt, H.; Yilmaz, H.R.; Ozugurlu, F.; Sivasli, E.; Yetkin, O.; Yanik, M.; Tutkun, H.; Savas, H.A.; Tarakcioglu, M. and Akyol, O..Changes in nitric oxide levels and antioxidant enzyme activities may have a role in the pathophysiological mechanisms involved in autism. *ClinChim Acta* . 2003; 331, P: 111–117 .

9. Meredith PA. Candesartan cilexetil- a review of effects on cardiovascular complications in hypertension and chronic heart failure. *Curr Med Res Op in* 2007;23, p:1693-1705.

10. de Gasparo M, Levens N. Does blockade of angiotensin II receptors offer clinical benefits over inhibition of angiotensin-converting enzyme? *Pharmacol Toxicol* 1998;82 , p:257–271.

11. Junqueira, L.C.; Carneiro, J. and Kelley, R.: Basic Histology. 8th Ed, Lange Medical Book, 1995; 30G-314G,p:1-2.

12. Evren Kose,¹ Hilal Irmak Sapmaz,¹ Ediz Sarihan,² Nigar Vardi,³ Yusuf Turkoz,⁴ and Nihat Ekinci. Beneficial Effects of Montelukast Against Methotrexate-Induced Liver Toxicity: A Biochemical and Histological Study. *The Scientific World Journal* Volume . 2012, 6 pages .

13. Van Belle G, Fisher LD, Heagerty PJ, Lumley, T Biostatistics: A method-ology for the health sciences. 519. John Wiley & Sons, 2004 .

14. Sugiyama S, Hayakawa M, Kato T, Hanaki Y, Shimizu K, Ozawa T. Adverse effects of anti-tumor

drug, cisplatin, on rat kidney mitochondria: disturbances in glutathione peroxidase activity. *Biochem Biophys Res* .1989; 159, p:1121–1127.

15. Kim, J. C., Kim, K. H., and Chung, M. K .Testicular cytotoxicity of DA-125, a new anthracycline anticancer agent, in rats. *Reprod Toxicol* .1999 ;13, p: 391–397.

16. Naldi L, Griffiths CE. Traditional therapies in the management of moderate to severe chronic plaque psoriasis: an assessment of the benefits and risks. *Br J Dermatol* . 2005;152, p:597–615.

17. Feagan BG, Alfadhli A , Methotrexate in inflammatory bowel disease. *Gastroenterol Clin North Am* . 2004; 33, p:407–420.

18. Baliga R, Ueda N, Walker PD, Shah SV. Oxidant mechanisms in toxic acute renal failure. *Drug Metabolic Rev* . 1999; 31, p:971–997.

19. Zhang JG, Zhong LF, Zhang M, Xia YX. Protection effects of procaine on oxidative stress and toxicities of renal cortical slices from rats caused by cisplatin in vitro. *Arch Toxicol*.1992; 66, p:354–358.

20. Hall PM, Jenner MA, Ahern MJ. Hepatotoxicity in a rat model caused by orally administered methotrexate. *Hepatology* 1991; 14, p:906–910.

21. Maiti R, Jana D, Das UK, Ghosh D. Antidiabetic effect of aqueous extract of seed of *Tamarindus indica* in streptozotocin-induced diabetic rats. *J Ethno-pharmacol*. 2004, 92, P: 85-91.

22. Wang, L.; Cheng, D.; Wang, H.; Di, L.; Zhou, X. and Xu, T. J. *Enthno-pharmacol*. 2009 ,126: 487-491.

23. Somachit MN, Sulaiman MR, Noratunlina R, Ahmad Z. Hepatoprotective effects of *Curcuma longa* Rhizomes in paracetamol-induced liver damage in Rats. *Proceeding of the Regional Symposium on Environment and Natural Resources, Kuala Lumpur, Malaysia*. 2002, 1, p: 698-702.

24. Fu Y, Zheng S, Lin J, Ryerse J, Chen A. Curcumin protects the rat liver from CCl₄-caused injury and fibrogenesis by attenuating oxidative stress and suppressing inflammation. *Mol Pharmacol* . 2008;73 (2), p: 399-409.
25. Uraz, S., Tahan, V., Aygun, C., Eren, F., Unluguzel, G., Yuksel, M., Senturk, O., Avsar, E., Haklar, G., Celikel, C., Hulagu, S., and Tozun, N. Role of ursodeoxycholic acid in prevention of methotrexate-induced liver toxicity. *Dig. Sci.* 2008; 53, p:1071-1077.
26. Vaghasiya, J., Bhalodia, Y. and Rathod, S. Drug induced hepatotoxicity : effect of polyherbal formulation . *PhcogMag* .2009 ; 5, p:232-237.
27. Jahovic N, Sener G, Ersoy Y, Arbac S, Yegen B.C. Amelioration of methotrexate-induced enteritis by melatonin in rats. *Cell Biochem Funct.* 2004, 22,p:169-178.
28. Mustafa C, etiner Go ksel S, enere, A. O zer S, ehirlie, Emel Eks, iog ˘lu-Demiralp, Feriha Ercan, Serap S, irvancN, Nursal Gedik, Sertac, Akpulat, Tulay Tecimer, Berrak C, Yeg ˘en . Taurine protects against methotrexate-induced toxicity and inhibits leukocyte death. *Toxicol Appl Pharmacol.*2005;209, P:39- 50
29. Sotoudehmanesh, R; Anvari, B; Akhlaghi, M. et al. Methotrexate Hepatotoxicity in Patients with Rheumatoid Arthritis. *Middle East J. Digest. Disease.* 2010; 2, P: 104-109.
30. Johovic, N., Cevik, H., Sehirli, O. A., Yegen, B. C, and S ˘ener, G. Melatonin prevents methotrexate-induced hepato-renal oxidative injury in rats. *Journal of Pineal Research* . 2003. 34, P: 282-287.
31. Cetin, A., Kaynar, L., Kocyigit, I., Hacıoglu, S. K., Saraymen, R., Ozturk, A., Sari, I., and Sagdic, O. Role of grape seed extract on methotrexate induced oxidative stress in rat liver. *American Journal of Chinese Medicine.* 2008, 36, p:1-12.
32. ALL C, Ertan B, Ergul BK, Bulent K. N-acetylcysteine ameliorates methotrexate-induced oxidative liver damage in rats. *Med Sci Monit.* 2006,12 (8), p:247-248.
33. Przybtkowski E, Averill-bates DA. Correlation between glutathione and stimulation of the pentose phosphate cycle in situ in Chinese hamster ovary cells exposed to hydrogen peroxide. *Arch Biochem Biophys.* 1996; 325, p:91-98.
34. Suh, J. H.; Shevni, S.V.; Dixon, B. M.; Liu, H.; Jaiswol, A. K.; Liu, R. M. and Hagen, T. M.: *Proc. Nat. Acad. Sci.* . 2004 ; 101, p: 3381-3386.
35. Walker TM, Rhodes PC, Westmoreland C. The differential cytotoxicity of methotrexate in rat hepatocyte monolayer and spheroid cultures. *Toxicol in Vitro.* 2000, 14, p: 475-485.
36. Uzar E , Koyuncuoglu H R , Uz E , Yilmaz H. R , Kutluhan S , Kilbas S and Gultekin F .The Activities of Antioxidant Enzymes and the Level of Malondialdehyde in Cerebellum of Rats Subjected to Methotrexate: Protective Effect of Caffeic Acid Phenethyl. *Mol. Cell Bioch.* 2006; 291, p: 63-68
37. Babiak RM, Campello AP, Carnieri EG, Oliveira MB. Methotrexate: pentose cycle and oxidative stress. *Cell Biochem Funct* .1998; 16, p:283-293.
38. Rouse K, Nwokedi E, Woodliff JE, Epstein J, Klimberg VS. Glutamine enhances selectivity of chemotherapy through changes in glutathione metabolism. *Ann Surg.* 1995, 221, p: 420-426.
39. Sirag, H.M., albrahim, H.A., a Amer, A.A., a Salam, T.A., b Samaka, R.M c and El-Mowafy, Y. A. Ameliorative effect of Caffeic Acid Phenethyl Ester and Candsartain Cilexetil on CCl₄ induced Hepatotoxicity in Male Rats . *Annals of Biological Research.* 2011, 2 (4), P: 503-515 .
40. Al-Motabagani, M A. Histological and Histochemical Studies on the Effects of

Methotrexate on the Liver of Adult Male Albino Rat.
Int. J. Morphol . 2006; 24, p:417-422

41. Chan EC, Jiang F, Peshavariya HM, Dusting GJ.\ Regulation of cell proliferation by NADPH-oxidase-mediated signaling: Potential roles in tissue repair, regenerative medicine and tissue engineering. Pharmacol Ther. 2009; 122(2) , p:97–108.

42. Bataller R, Gäbele E, Parsons CJ, Morris T, Yang L, Schoonhoven R, Brenner DA, Rippe RA. Systemic infusion of angiotensin II exacerbates liver fibrosis in bile duct-ligated rats. Hepatology. 2005; 41(5), p:1046–1055.

43. Ramadan A. M. Hemeida. Ihab T. Abdel-Raheem, Gamal A. El-Sherbiny El-Shaimaa A. Arafa, Abdel-Gawad S. Candesartan modulates the antioxidant effect of silymarin against CCl₄-induced liver injury in rats.

44. Tahssein Ali Mohammed, Adeeb A. Al-Zubaidy, Yarub I. Khattab. The Possible Protective Effects of Candesartan cilexetil Against Methoteraxte Induced Nephrototoxicity In Rabbits. International Journal of Advanced Research (2014), Volume 2, Issue 12, 315-325.

45. Hall PD, Jenner MA, Ahern MJ. Hepatotoxicity in a rat model caused by orally administered methotrexate. Hepatology. 1991,14; p:906–910 .

46. Asci, H., Ozer, M. K., Calapoglu, M., Savran, M., Oncu, M., Yesilot, S., Candan, I. A., Kulac, E. and Cicek, E. Effects of misoprostol on methotrexate induced hepatic and renal damages. 2011, 2(1); p: 32-37.

Table 1:

GROUP (N= 6)	AST U/L	ALT U/L	ALP U/L	MDA-LIVER Mmol /g. tissue	GSH-LIVER Mmol /g. tissue
(GROUP I)	28.86 ± 3.97	68.63 ± 4.39	40.37 ± 2.24	26.49 ± 2.26	24.04 ± 2.1
(GROUP IIA)	69.82 ± 5.5 a	105.9 ± 2.25 a	64.23 ± 2.69 a	52.47 ± 3.55 a	6.53 ± 2.25 a
(GROUP IIB)	43.01 ± 6.11 NS, b	81.19 ± 3.8 NS, b	46.1 ± 3.32 NS, b	34.39 ± 3.26 NS, b	19.02 ± 1.88 NS, b
(GROUP IIIA)	83.96 ± 5.81 a	111.5 ± 4.09 a	88.22 ± 3.85 a	61.72 ± 5.53 a	4.37 ± 0.91 a
(GROUP IIIB)	36.95 ± 2.48 c, N.S	72.44 ± 5.14 c, N.S	45.82 ± 2.79 c, N.S	28.46 ± 2.98 c, N.S.	20.69 ± 1.36 c, N.S.

Data are presented as Mean ± SEM , N = number of animals per group , Group I : control group , Group II-A : MTX 20mg/kg , Group II-B : (MTX 20mg/kg + CAND. 10mg/kg) , Group III-A: MTX 100mg/kg , Group III-B : (MTX 100 mg/kg + CAND. 10mg/kg), a : p < 0.05 significant in compare to control group , b : Significant to MTX 20 mg/kg , c : Significant to MTX 100 mg/kg , NS : Non Significant to control group

Table 2:

GROUP (N=6/group)	Liver Score (Mean \pm Std. Error of Mean (SEM))
GP-I	0.00 \pm 0.00
GP-IIA	2.45 \pm 0.21 (a)
GP-IIB	1.27 \pm 0.15 (a,b)
GP-IIIA	3.81 \pm 0.16 (a)
GP-IIIB	1.74 \pm 0.28 (a,c)

Data are presented as Mean \pm SEM , N = number of animals per group , Group I : control group , Group IIA : MTX 20mg/kg , Group IIB: (MTX 20mg/kg+CAND.10mg/kg) , Group IIIA:MTX100mg/kg , Group IIIB: (MTX 100 mg/kg+CAND.10mg/kg) , a: p<0.05 significant in compare to control group, b:Significant to MTX20 mg/kg , c: Significant to MTX100 mg/kg

Figure 1: Effects of candesartan treatment on the serum levels of AST in rabbits compared to control and MTX induction groups

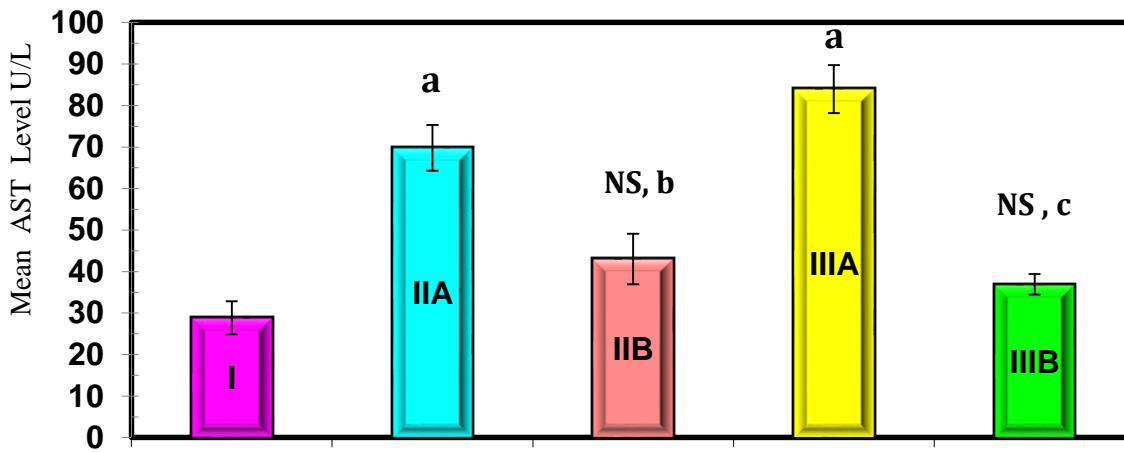


Figure 2: Effects of candesartan treatment on the serum levels of ALT in rabbits compared to control and MTX induction groups

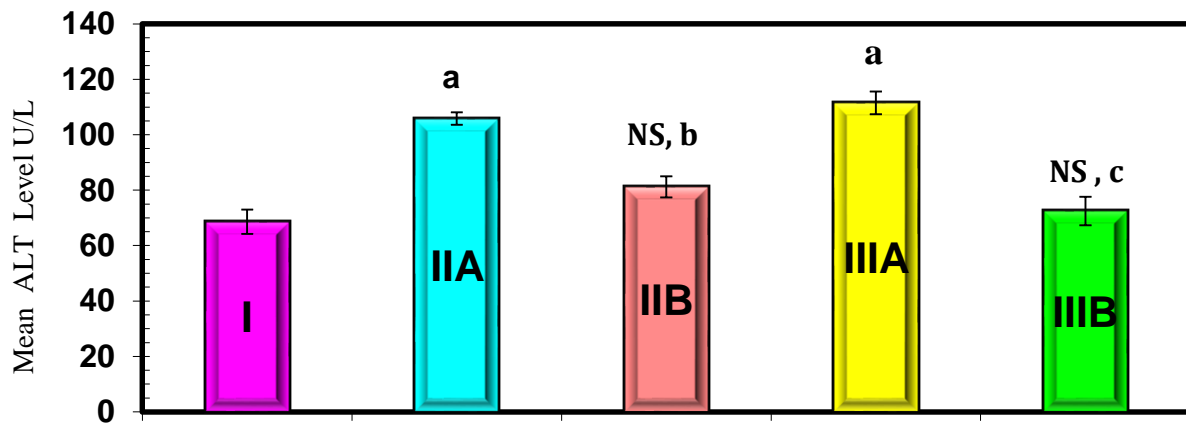


Figure 3: Effects of candesartan treatment on the serum levels of ALP in rabbits compared to control and MTX induction groups

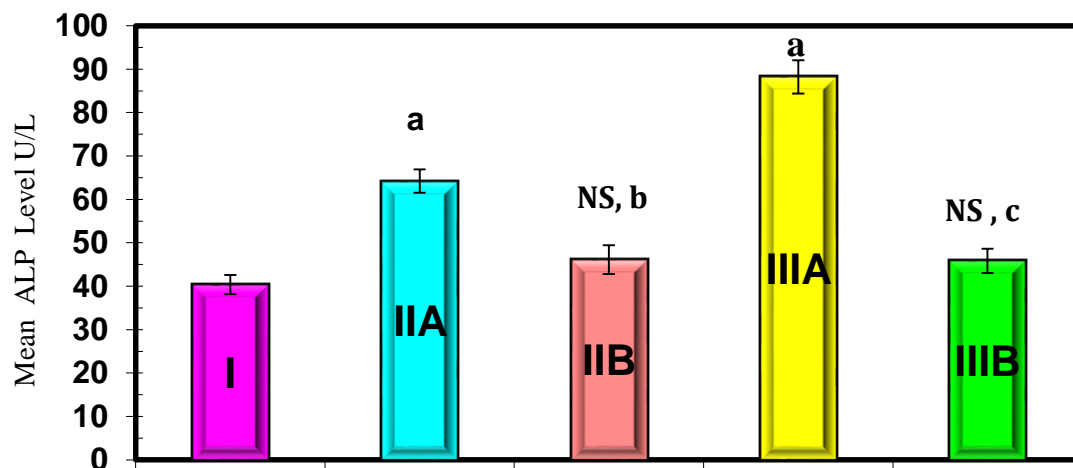


Figure 4: Effects of candesartan treatment on the levels of MDA in liver tissue homogenate in rabbits compared to control and MTX induction groups

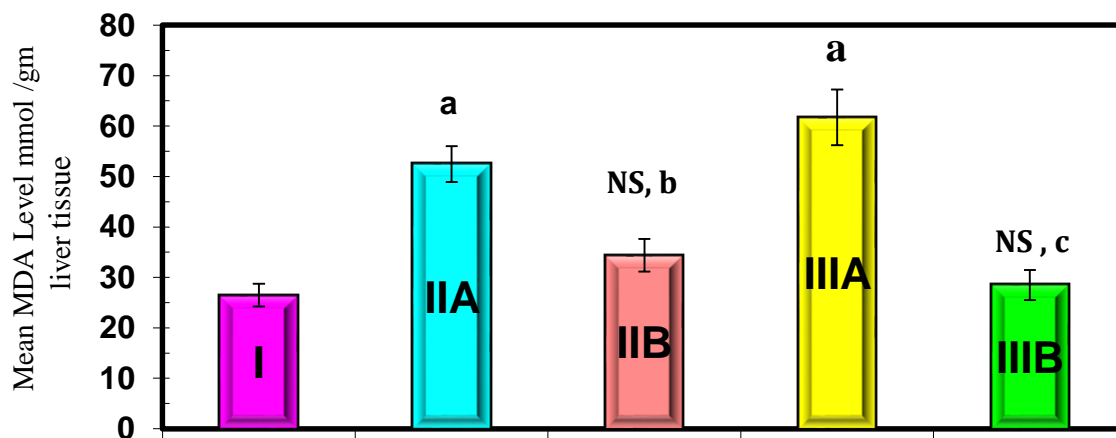


Figure 5: Effects of candesartan treatment on the levels of GSH in liver tissue homogenate in rabbits compared to control and MTX induction groups

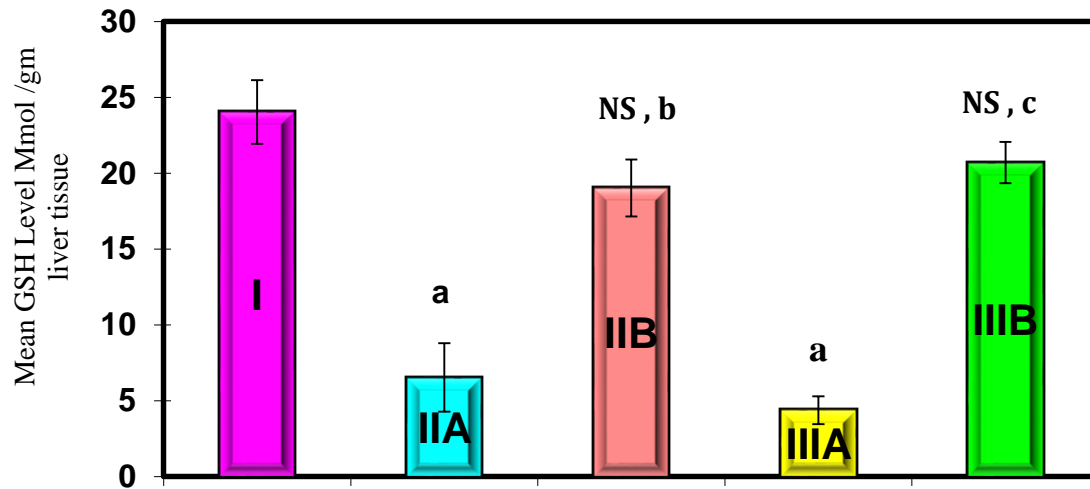
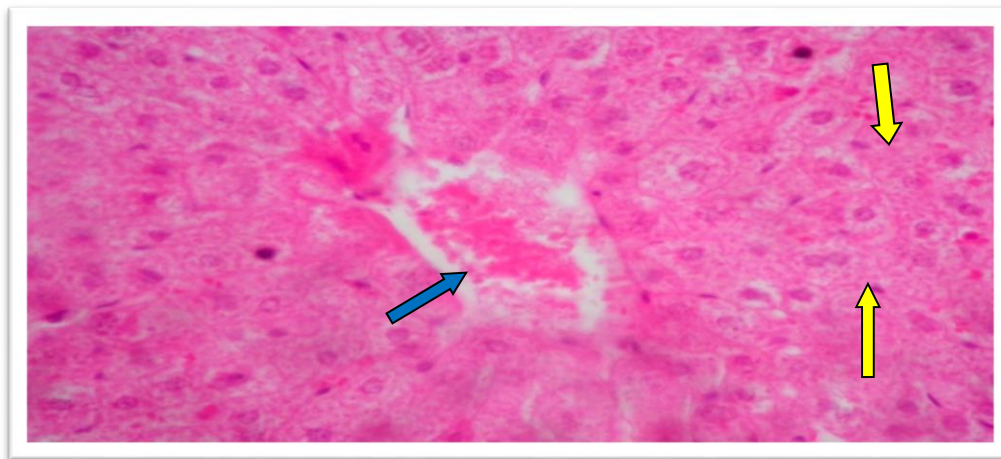


Figure (1): Section of liver of group I (control group) shows normal central vein (blue arrow) and normal hepatocytes (yellow arrow) - score number (1) . H&E (40X)



Figure(2): Section of liver of groupII-A (MTX 20mg/kg) shows scattered hepatocyte vacuolization moderate hydropic degeneration(green arrow),obvious piecemeal necrosis(blue arrow) , bile duct proliferation (yellow arrow) score number (3) . H&E (40X) .

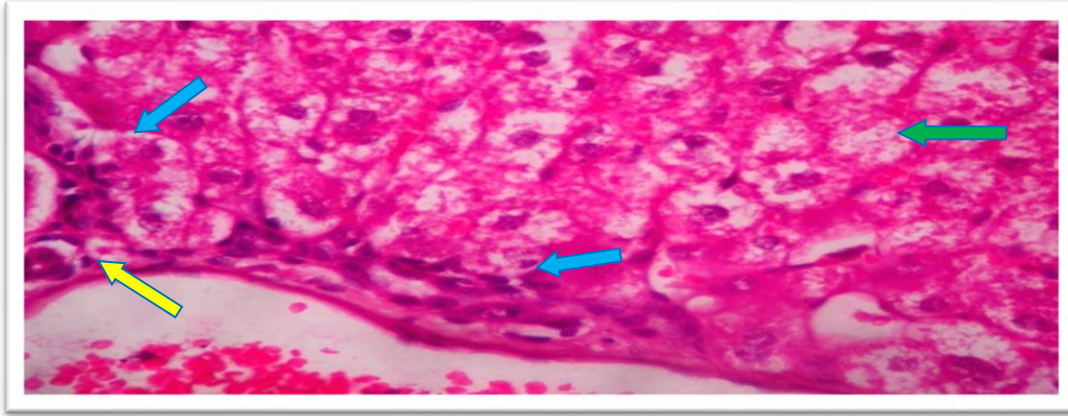


Figure (3): Section of liver of groupII-B (Candesartan 10mg/kg/day for 10days with Methotrexate 20mg/kg) shows disappearance of hydropic degeneration with mild traditis(blue arrow) with normal bile duct (yellow arrow) score number (2). H&E (40X) .

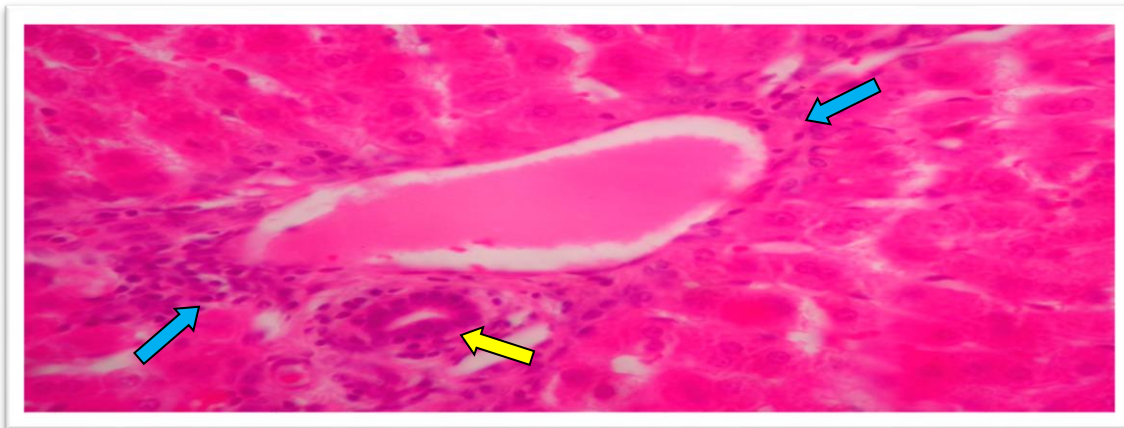


Figure (4): Section of liver of group IIIA (MTX 100mg/kg) shows sever hydropic degeneration with hepatocyte hydropic feathery (yellow arrow) and port portal bridging (blue arrow) with scattered hepatocytic vacuolization (green arrow) - score number (4) . H&E (40X) .

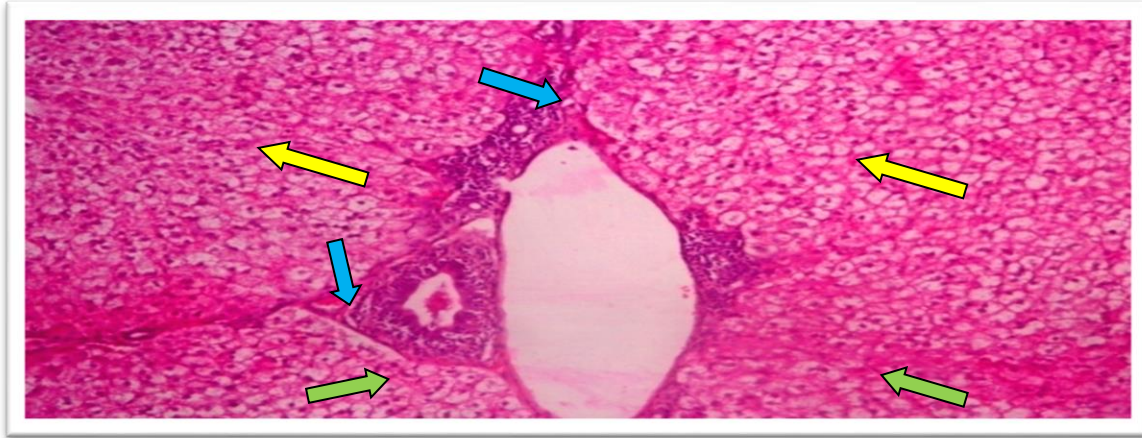


Figure (5): Section of liver of group IIIB (Candesartan 10mg/kg/day for 10days with MTX 100mg/kg) shows mild hydropic degeneration (yellow arrow) with less feathery changes- score number (2). H&E (40X)

