



## Natural Outbreaks of Infectious Bursal Disease in Brahma and Aseel Chicken in Iraq

Waleed Majeed Seger<sup>1</sup>, Qayssar Ali Kraidi<sup>2\*</sup>, Talal Jabal Hussien<sup>1</sup>, Mukhallad Abdul Kareem Ramadhan<sup>3</sup>

<sup>1</sup>. Department of Pathology and Poultry Diseases, Faculty of Veterinary Medicine, University of Basra, Basra, Iraq.

<sup>2</sup>. Department of Animal Production, Faculty of Agriculture, University of Misan, Misan, Iraq.

<sup>3</sup>. Department of Pathology, Faculty of Medicine, University of Misan, Misan, Iraq .

\*Correspondence Author: Qayssar Ali Kraidi

### Abstract

The infectious bursal disease (IBD) represents one of the most severe poultry diseases and is responsible for marked economic losses in poultry populations in Iraq. Backyard chicken with different breeds have been recently raised successfully in a rural area for hobby and household consumption, however, the status of the disease in free-ranging backyard chickens in Iraq is not documented, for this reason, the objective of the present study was to determine the disease in free-range poultry naturally infected with IBDV currently circulating in Iraq. A tentative diagnosis of IBD was conducted based on clinical findings, gross lesions besides the histopathology and lesion scoring analysis and was confirmed by identification of IBDV antigen in AGPT. Typical IBD clinical signs and lesions were observed in all types of birds with a high mortality rate (30% & 25%) reported in Aseel and Brahma breeds, respectively. Histopathological lesion scores analysis for IBDV characterized by a high lesion score of (+5) observed in the studied birds of all breeds. Based on the results of high mortality rate and high histopathological lesion scores we can suggest the occurrence of the disease in backyard chicken in Iraq associated with pathogenic field IBD virus. The present study provides first background document on the current status of IBD in free-range poultry in Iraq.

**Keywords:** *Aseel, Brahma, IBD, Iraq.*

### Introduction

Infectious bursal disease (IBD), also known as Gumboro, is caused by IBD virus which especially elicits a highly contagious infection of young chickens causing severe economic and production losses worldwide [1]. The etiological agent of IBD is a non-enveloped, double-stranded dsRNA virus, which is under the genus Avibirnavirus and is a member of the family Birnaviridae with a bisegmented dsRNA genome [2, 3].

There are two distinct serotypes of IBDV, and within each serotype antigenic variation is considerable, serotype 1 is pathogenic to chickens in which it causes infection, while serotype 2 is a pathogenic. Serotype 1 IBDV can be further classified as classic virulent, subclinical, and very virulent (vv) Pathotypes.

The two serotypes neither cross-protect nor cross-neutralize each other [4]. This virus primarily targets lymphoid tissue and infects IgM-bearing B-lymphocytes in the bursa of Fabricius, leading to extreme immunosuppression [5]. Regardless of when the infection occurs the IBD causes immune-suppression which makes the chicken vulnerable to a variety of secondary infections.

As a result, infected birds develop a poor immune response to vaccination against other pathogens [6]. In fully susceptible chicken flocks (3 - 6 weeks of age), the disease is responsible for severe losses due to impaired growth and death, and from an excessive condemnation of carcasses because of skeletal muscular hemorrhages [7].

Susceptible chickens less than three weeks of age do not exhibit clinical signs [8] but have a subclinical infection characterized by microscopic lesions in the Bursa of Fabricius and immunosuppression [2,9]. The seroprevalence studies showed that IBD is an endemic and widely distributed disease in free-range village chickens in Tanzania and Ethiopia [10, 11], also the seroprevalence of IBDV has been demonstrated in free-living wild birds in Japan including migratory species [12].

The IBDV represents one of the most severe poultry diseases and is responsible for marked economic losses in poultry populations, especially 28 (36.8 %) of poultry farms in north of Iraq were infected with IBD during the period from October 2012 to March 2013 and the topology of the phylogenetic tree indicated that the Iraqi IBD field isolates belong to very virulent IBDV strains that contain Indian and Egyptian isolates [13].

Although backyard chicken with different breeds have been recently raised successfully in a rural area for hobby and household consumption, however, the status of the disease in free-ranging backyard chickens in Iraq is not documented, for this reason, the objective of the present study was to determine the disease in free-range poultry naturally infected with IBDV currently circulating in Iraq.

## Materials and Methods

### Flock History

Outbreaks of IBD were reported in 2018 in two backyard poultry flock of mixed age groups from 2 households, in addition to one commercial broiler flocks. All flocks located in the different location of Basra province in the southern part of Iraq. One of the affected backyard flock composed from Asil or Aseel breed and the other composed from Brahma breed with bird population consisted from 30 and 150 bird in Aseel and Brahma flocks, respectively (Table 1).

The indigenous flocks maintained chicken for hobby and household consumption. Their detailed information's on flock management, date and age of outbreak, vaccination programs, clinical signs, and mortality were recorded. The chickens in the all affected (backyard and commercial) flocks were unvaccinated against IBD.

## Sample Collection and Preparation

Freshly carcasses or severely-ill birds from field outbreaks of suspected IBD backyard flocks were examined for postmortem lesions. Sera samples were collected and used for serological examination and the Bursa of Fabricius (BFs) was aseptically harvested and tested for the detection of IBD virus and for histopathological examination.

### Processing of BFs Samples

BFs were harvested from five birds of each breed, chopped and homogenized into 50% (w/v) suspension in phosphate buffered saline. The homogenate suspension of the organs was centrifuged at 2000 rpm for 30 minutes and the supernatant fluid was harvested and tested for IBD antigen by the agar gel precipitation test (AGPT).

### Agar Gel Precipitation Test (AGPT)

This test was implemented in the Department of Veterinary Pathology and poultry diseases at the University of Basra/Iraq. Presence of the viral antigen in the BFs was confirmed using (AGPT). The test was performed following the procedures described by [14].

Briefly, the central well of a glass slide coated with melted agarose gel was loaded with known antiserum against IBDV and peripheral wells with reference antigen of IBDVs and bursal suspensions. Slides were kept in a moist chamber for 48-72 hours at 40 °C and observed for antigen-antibody reaction in the form of appearance of precipitation lines in between the central and peripheral wells.

### Histopathology and Lesion Scoring

Tissue samples of BFs were subsequently collected in 10% neutral buffered formalin and used for histopathological examination. The tissues were processed and the 5  $\mu$  thick tissue sections were cut out of the paraffin-embedded tissue blocks and stained with hematoxylin and eosin staining as per the protocol and examined under a light microscope.

Histopathological lesion score was carried out by using the criteria of [15] with a scoring range of 0 to 5 (0, normal bursal follicle architecture and 5, complete loss of bursal).

## Statistical Analysis

The studied data were analyzed for statistical significance using t test. A p-value <0.05 was considered as significant.

## Results

### Clinical Signs

The affected birds of all breeds showed similar clinical signs, included anorexia, sleepiness with ruffled feathers, white watery to yellow mucoid diarrhea, reluctance to move, droopy appearance (Fig. 1,2), depression, trembling, prostration and death. High mortality rate (30%) was reported in Aseel breed, while 25%, 18% mortality rate was reported in Brahma and broiler, respectively (table 1). The disease was recorded in fully susceptible age (40 - 42 days of age) in all studied breeds.

### Gross Lesions

Typical IBD lesions were observed in all types of birds; they included enlarged BF's which were also covered by straw-colored gelatinous material (Fig.3), and caseous

necrotic debris was observed in the lumen the swollen bursa. Intrafollicular hemorrhages were present (Fig. 4, 5). The bursa was completely hemorrhagic giving the appearance of a red cherry which was only seen in the broiler.

Numerous ecchymotic and petechial hemorrhages in the thigh muscle (Fig. 6, 7). Enlargement of the kidneys with urate-distended tubules. Catarrhal enteritis with mucus in the small intestine was common. Hemorrhages on the mucosal surface of the proventriculus and proventriculus-gizzard junction in the affected birds were not seen in all breed.

### Histopathology and Lesion Scoring

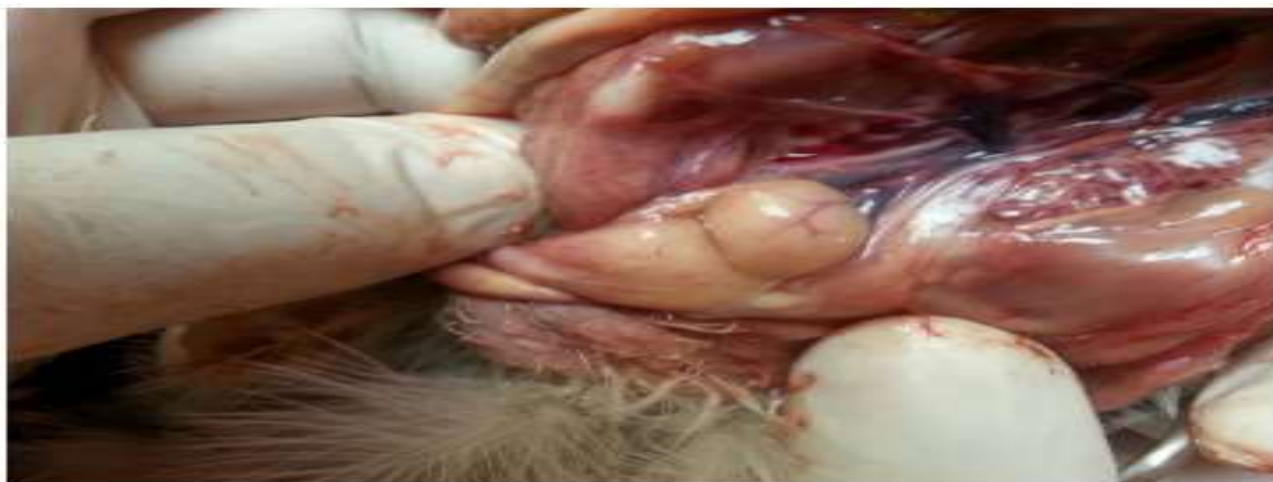Analysis of paraffin-embedded tissue blocks based on histopathological lesion scores for IBDV characterized by the presence of high lesion scores of +4 or +5 (having marked depletion of lymphocytes with a cystic formation in most of the bursal follicles, Fig.8 to 12); were observed in the studied birds of all breeds( Table, 1).



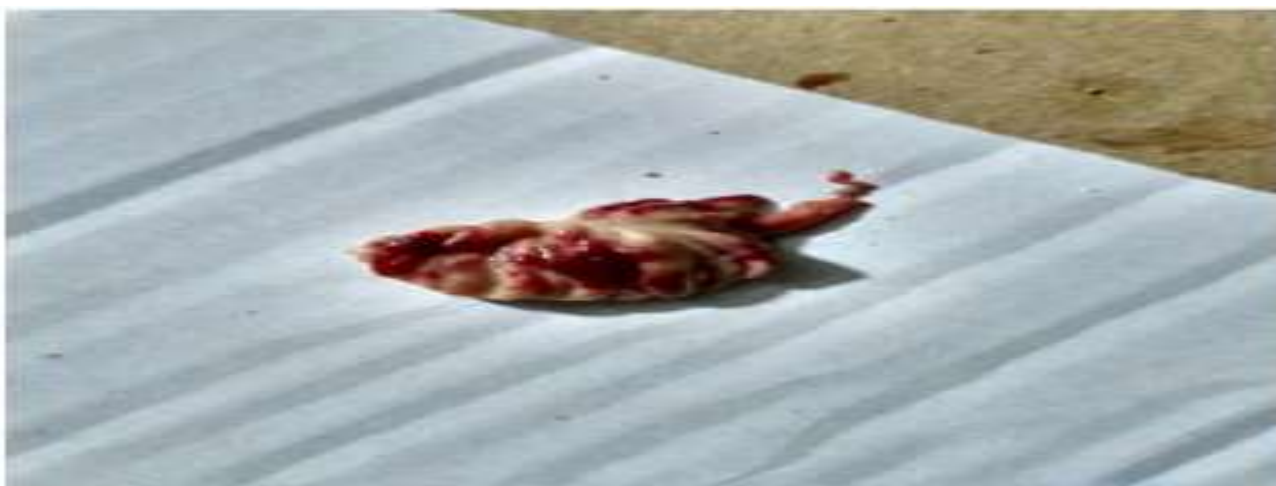Fig. 1: Yellow mucoid diarrhea in Brahma chicken infected with IBDV



Fig. 2: Affected Brahma chicken showing clinical signs of severe depression and prostration



**Fig. 3: Enlarged BFs covered by straw-colored gelatinous material in Brahma chicken**



**Fig. 4: Sever Intrafollicular hemorrhages in BFs in Aseel chicken**



**Fig. 5: Edema and Intrafollicular hemorrhage in BFs of Brahma chicken**



**Fig. 6: Numerous ecchymotic and petechial Hemorrhages in the thigh muscle of Brahma chicken**



Fig. 7: Numerous ecchymotic and petechial Hemorrhages in the thigh muscle of Aseel chicken

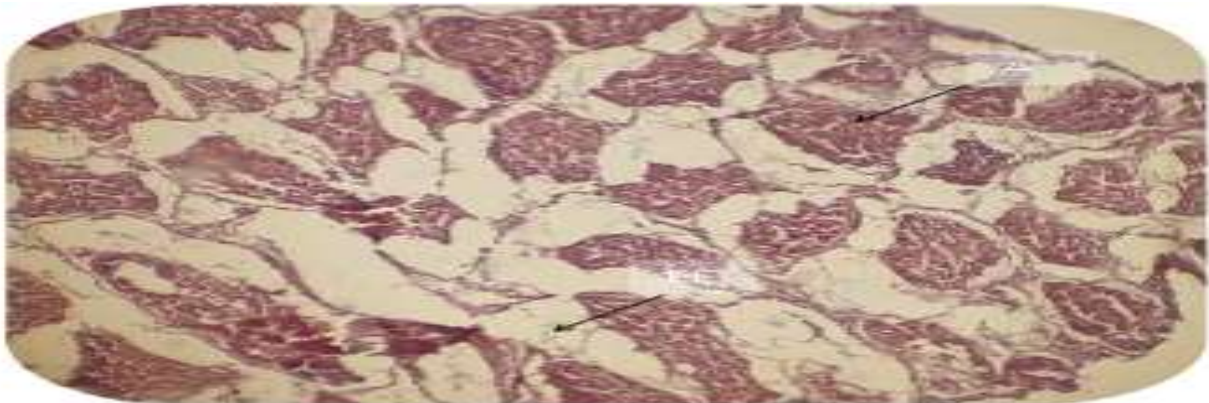


Fig. 8: A section of bursa in brahma chicken reveals atrophic follicles (AF) with accumulation of edema fluid (EF) in the site of change. H&E; 125X

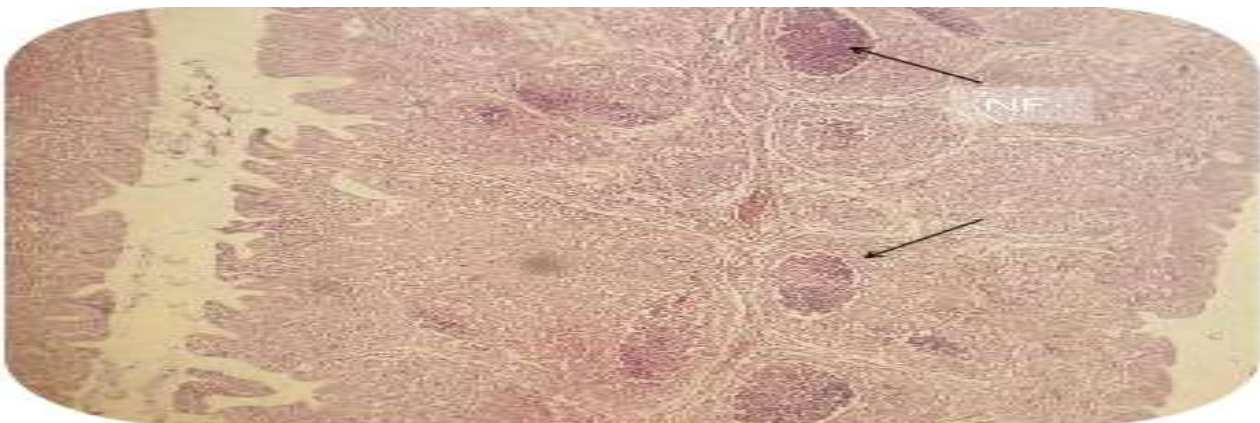


Fig. 9: A section of bursa in brahma chicken reveal necrosis in the follicular center (NF) with some follicles contain tissue debris (TD), others contain cystic dilation (CD) H&E 125X

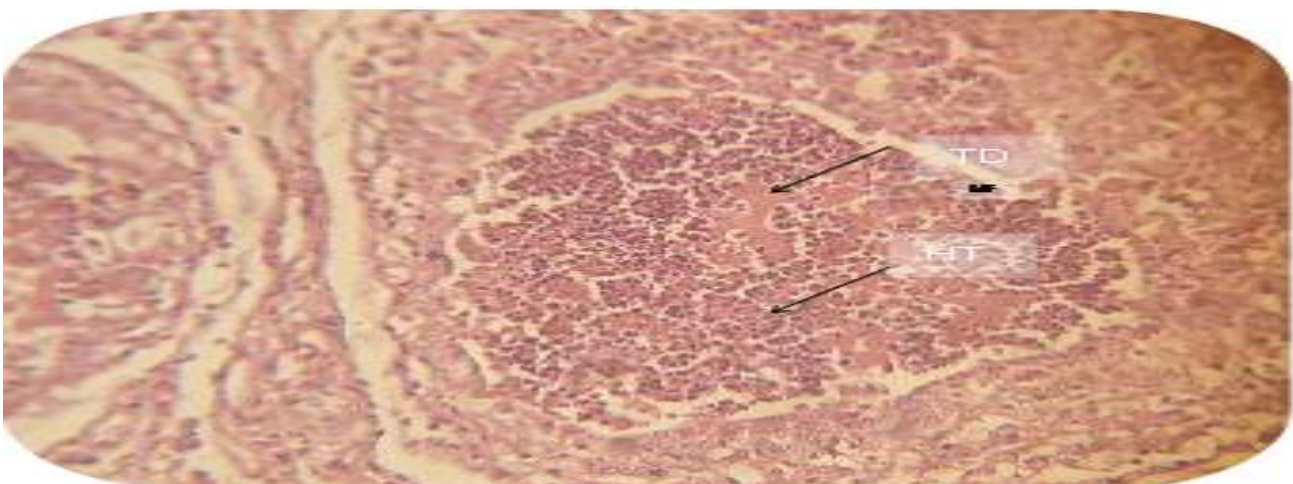


Fig. 10: A section of bursa in brahma chicken reveal necrosis in the follicular center (NF) with sever hetrophelia (HT) and tissue debris (TD) H&E 500X

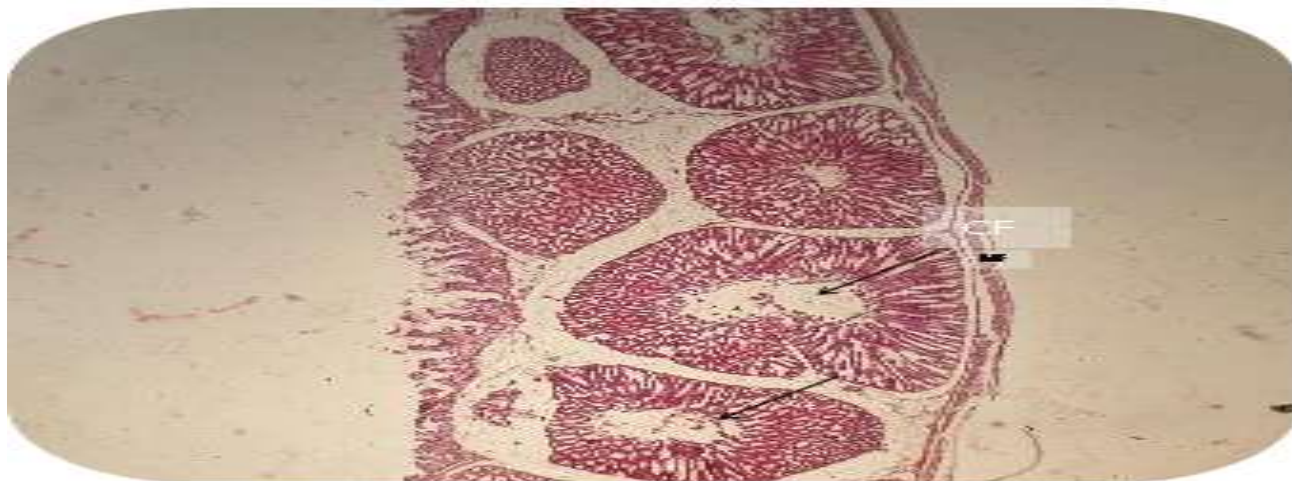


Fig. 11: A section of bursa in Aseel chicken reveals marked depletion in lymphocytes with cystic follicles (CF) H&E 50X

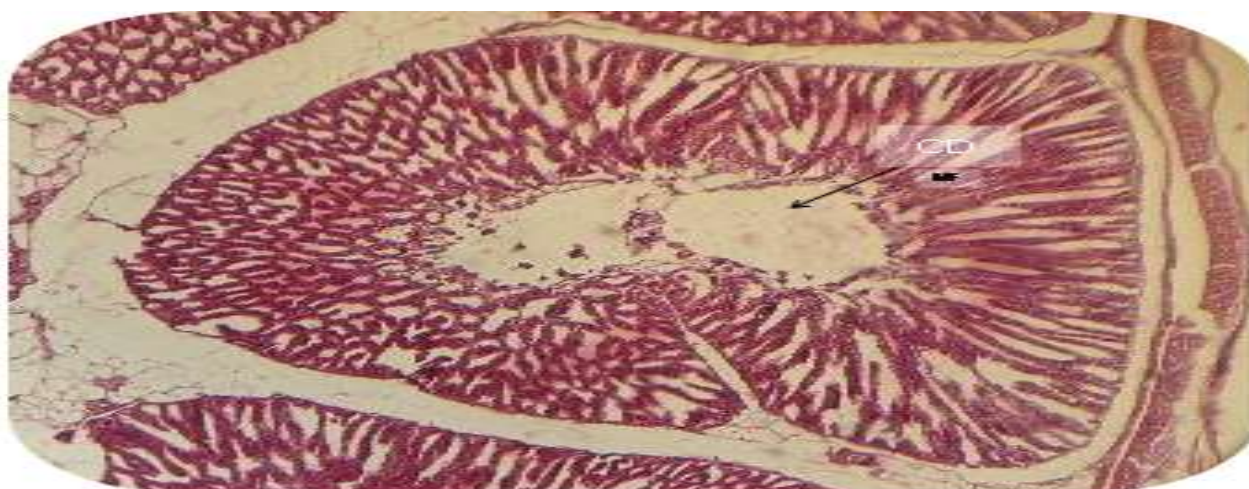


Fig. 12: A section of bursa in Aseel chicken reveals marked depletion in lymphocytes with cystic follicles (CF) H&E 500X

Table 1: Flock size, breed, and mortality rate and mean bursal lesion score during IBD outbreaks in Basra

Flock No.	Chicken breed	Flock size	Mortality rate	Mean bursal lesion score	t-value*	p-value
Flock 1	Asil or Aseel	30	30%	4.72 <sup>a</sup>	5.18	0.00041
Flock 2	Brahma	80	25%	4.64 <sup>b</sup>	3.391	0.0047
Flock 3	Ross 308	6000	18%	4.44 <sup>b</sup>	3.05	0.0078

Means with different subscripts differ significantly (p<0.05)

### IBD Confirmation

All the BFs harvested from the affected indigenous and commercial chicks were positive for IBDV antigen by AGPT test they showing clear distinctly visible precipitation lines against the reference antiserum within 36 - 48 hours post incubation.

### Discussion

The present study focused on the detection of IBDV in a different indigenous and commercial broiler breed by evaluating the clinical observations and the sequential pathological changes in BFs of the affected birds in each breed during a natural infection with an IBDV currently circulating in Iraq. A tentative diagnosis of IBD was conducted

based on clinical signs and gross lesions besides the histopathology and lesion scoring analysis and was confirmed by identification of IBDV antigen in AGPT. The affected birds of all breeds showed similar clinical signs and higher mortality rate (30% & 25%) was reported in Aseel and Brahma breeds, respectively, while 18% mortality rate was reported in broiler chicks and these results were in accordance with [16]who referred to that IBD caused a high mortality rate in Black Harco chicken in Nigeria.

Field observations with mortality reaching 30 to 40% or more are also valuable indicators of the vvIBDV phenotype, besides to another acceptable criterion for characterization of isolates as vvIBDV [17].

High mortality (30%) recorded in the current study might suggest that the virus circulated in the backyard flock in Iraq was a vvIBDV, in particularly the topology of the phylogenetic tree indicated that Iraqi IBD field isolates obtained from commercial broiler flocks belong to very virulent IBDV strains that contain Indian and Egyptian Isolate[13]. In the present study, broiler flock showed a low mortality rate (18%) in comparison with Aseel and Brahma breeds, this result is in line with experimental results of [18]who revealed that local Nigerian chickens are more susceptible to IBD than broilers and the total of mortality rate was 17.6% and 61.51% in broiler and local Nigerian chickens, respectively.

The field observations of this study confirmed the earlier reports which explained that mortality rate due to IBD infection was higher in light breeds of chicken than in broilers or heavy breeds [19, 20]. The disease was recorded in fully susceptible age (40 - 42 days of age) in the affected birds of all studied breed in this study. It has been reported that the highest susceptibility to acute clinical IBD occurs in chickens between 3 and 6 weeks of age when the BFs is at its maximum development [18], and the period of 4 to 8 weeks of age has been reported to represent the plateau phase of bursa growth [21]. Typical IBD lesions were observed in all types of birds and the main gross lesions during the acute phase of virulent IBDV currently circulating in Iraq were in the BFs.

It has been stated by [17] that the bursae of chickens infected with virulent serotype 1 IBDV appeared yellowish (sometimes hemorrhagic) with black cherry appearance and turgid, with prominent striations. The association of hemorrhages on the mucosal surface of the proventriculus and proventriculus-gizzard junction were not seen in all studied breeds goes in accordance with the earlier results by [22, 23], who also found that naturally occurring proventriculitis can occur in the absence of IBDV and the IBDV tested do not directly produce proventriculitis.

It's known that virulence of IBDV strain is measured by a lesion severity score and confirmed by high histopathological lesion [24]. The presence of high histopathological lesions score (+5) on the BFs in the birds of all breeds confirmed the pathogenicity of the

field IBD virus. The presence of clinical signs and mortality in backyard breeds in the current study is conflicted with the suggestion of [25] who mentioned that Bhutanese native chickens are relatively immune tolerant to natural IBD infections compared to commercial layer strains based on lacking clinical signs and mortality in addition to that Bhutanese chickens possess protective antibody titers similar to the affected commercial chicken type in farms with IBD outbreak. However, under both natural and experimental conditions of IBD infection, the clinical signs and mortality were reported in Black Harco chicken in Nigeria and in indigenous chicken in Kenya [16, 26].

Based on the type of chicken-specific rate results of [27] the local Malaysian chickens had the highest rate of (19%) of IBD compared to other types of chicken in the northern region of Malaysia during the period from 2006 to 2016. Indigenous birds are believed to be resistant to classical strain of IBD virus for unknown reasons, in spite of that the result of this study was reported IBD infection in Aseel and Brahma breed in Iraq and this finding is similar to the experimental finding of [28] who mentioned that the very virulent IBD virus caused the disease in Indian native Aseel chicks. In addition, the genetic resistance results of native Egyptian breeds to challenge with vv IBDV revealed 35% and 55% mortality rate in Sina and Dandra breeds, respectively [29]. It seems that resistance to infectious diseases may be disease-specific [30, 31].

## Conclusion

In Iraq, Aseel and Brahma chicken are reared in the backyards for hobby and household consumption and are most likely not protected by vaccination against IBDV; thus more prone to be infected with IBD. And the present study provides first background information on the current status of IBD in free-range poultry in the southern part of Iraq.

Consequently, farmers and fanciers should be properly educated to improve the biosecurity with appropriate disinfectants as well as vaccination are still important in the effective control of the disease to minimize transmission of disease in Iraq flocks.

## Acknowledgments

The authors are acknowledged to Misan and Basra Universities for the support to conduct this study.

## References

- Müller H, Islam MR, Raue R (2003) Research on infectious bursal disease the past, the present and the future. *Veterinary Microbiology*, 97(1-2): 153-165.
- Kibenge FS, Dhillon A, Russell R (1998) Biochemistry and immunology of infectious bursal disease virus. *Journal of General Virology*, 69: 1757-1775.
- Liu M, Vakharia VN (2004) VP1 protein of infectious bursal disease virus modulates the virulence in vivo. *Virology*, 330(1): 62-73.
- Eterradossi YS (2013) Infectious Bursal Disease. In: *Diseases of Poultry*. 13th Ed, DE Swayne (Ed) John Wiley and Sons Inc, Ames, Iowa, USA, 219-246.
- Caston K (2008) Infectious Bursal Disease Virus (IBDV): Segmented Double-Stranded RNA viruses. In: *Structure and Molecular Biology*. Caister Academic Press, 133.
- Mazariegos LA, Lukert P, Brown J (1990) Pathogenicity and immunosuppressive properties of infectious bursal disease "intermediate" strains. *Avian diseases*, 34(1):203-208.
- Lukert, P D, Saif, YM (2003) Infectious bursal disease. In: *Diseases of Poultry*. 11th Ed, B W Calnek (Ed) Iowa State University Press, Ames, Iowa, USA, 161-179.
- Hitchner S (1971) Persistence of parental infectious bursal disease antibody and its effect on susceptibility of young chickens. *Avian diseases*, 15(4):894-900.
- Toro H, Van Santen V, Hoerr F, Breedlove C (2009) Effects of chicken anemia virus and infectious bursal disease virus in commercial chickens. *Avian diseases*, 53(1):94-102.
- Swai E, KESSY M, Sanka P, Mtui P (2011) A serological survey for infectious bursal disease virus antibodies in free-range village chickens in northern Tanzania. *Journal of the South African Veterinary Association*, 82(1): 32-35.
- Surafel A, Wassie M (2012) Seroprevalence of Infectious Bursal Disease in Backyard Chickens of North West Ethiopia. *Bulletin of Animal Health and Production in Africa*, 1(1):20-25.
- Ogawa M, Wakuda T, Yamaguchi T, Murata K, Setiyono A, Fukushi H, Hirai K(1998) Seroprevalence of infectious bursal disease virus in free-living wild birds in Japan. *Journal of Veterinary Medical Science*, 60: 1277-1279.
- Nawzad A, Nahla M, Shilan F, Zana HM (2016) Detection and Identification of Infectious Bursal Disease Virus in Broiler Farms in Sulaimani Province. *Int'l Journal of Advances in Chemical Eng. & Biological Sciences*, 3(1):39-43.
- Wood G, Muskett J, Hebert CN, Thornton DH (1979) Standardization of the quantitative agar gel precipitin test for antibodies to infectious bursal disease. *Journal of biological Standardization*, 7(2): 89-96.
- Williams A, Davison T (2005) Enhanced immunopathology induced by very virulent infectious bursal disease virus. *Avian pathology*, 34(1):4-14.
- Igwe A, Nwachukwu O, Chinyere C, Shittu I (2017) Evaluation of pathological changes of natural infectious bursal disease virus infection in the lymphoid organs of Black Harco pullets. *Sokoto Journal of Veterinary Sciences*, 15(2): 18-28.
- OIE (2016) Chapter 2. 3. 12. Infectious bursal disease (Gumboro disease) In: *OIE Manual of Diagnostic Tests and Vaccines for Terrestrial Animals Version adopted in Paris.2016*. <http://www.oieint/en/international-standard-setting/terrestrial-manual/access-online/>: 1-21.

## Author's Contribution

Dr. Waleed Majeed Seger designed the experiment, collected data, Dr. Talal jabal helped in statistical analysis, Dr. Mukhallad Abdul Kareem helped in laboratory analyses; while Dr.Qayssar Ali Kraidi wrote, commenting and approval of the paper.



18. Okoye J, Aba-Adulugba E (1998) Comparative study of the resistance or susceptibility of local Nigerian and exotic chickens to infectious bursal disease. *Avian pathology*, 27(2):168-173.
19. Van Den Berg T, Gonze M, Meulemans G (1991) Acute infectious bursal disease in poultry: isolation and characterization of a highly virulent strain. *Avian pathology*, 20:133-143.
20. Nunoya T, Otaki Y, Tajima M, Hiraga M., Saito T (1992) Occurrence of acute infectious bursal disease with high mortality in Japan and pathogenicity of field isolates in specific-pathogen-free chickens. *Avian Diseases*, 36. (3): 597-609.
21. Taylor R, McCorkle F (2009) A landmark contribution to poultry science immunological function of the bursa of Fabricius. *Poultry science*, 88(4):816-823.
22. Pantin-Jackwood MJ, Brown TP (2003) Infectious bursal disease virus and proventriculitis in broiler chickens. *Avian diseases*, 47(3): 681-690.
23. Grau-Roma L, Marco A, Martínez J (2010) Infectious bursal disease-like virus in cases of transmissible viral proventriculitis. *Veterinary Record*, 167: 836.
24. Hamoud MM (2006) Studies on infectious bursal disease virus (IBDV) dsRNA extracted from formalin fixed paraffin embedded tissue. (Doctoral dissertation, uga).
25. Tenzin S, Gurung R (2016) Immunological tolerance of Bhutanese native chicken to Infectious Bursal Disease Virus infection. *International Journal of Advanced Scientific Research and Management*, 1(2):46- 49.
26. Mutinda W, Njagi L, Nyaga P, Bebora L, Mbuthia P, Kemboi D, Githinji J, Muriuki A (2015) Isolation of Infectious Bursal Disease Virus Using Indigenous Chicken Embryos in Kenya. *International scholarly research notices*, 2015:1-7.
27. Thenamutha M, Sarenasulastri A, Rafidah A, Saipul Bahari A (2017) Distribution of Infectious Bursal Disease (IBD) diagnosed in northern region of Malaysia from year 2006 TO 2016. *Malaysian Journal of Veterinary Research*, 8(2):42-46.
28. Prabhu SN, Singh A, Varghese B, Kumar MA, Palanivelu M, Dhama K, Singh S, Singh R (2017) Comparative study of very virulent infectious bursal disease virus induced bursal pathology in experimentally infected Indian native Aseel and exotic White Leghorn chicken. *Indian Journal of Veterinary Pathology*, 41(2):94-101.
29. Hassan M, Afify M, Aly M (2004) Genetic resistance of Egyptian chickens to infectious bursal disease and Newcastle disease. *Tropical Animal Health and Production*, 36(1):1-9.
30. Sharaf M, Nestor K, Saif Y, Sacco R, Havenstein G (1998) Antibody response to Newcastle disease virus and *Pasteurella multocida* of two strains of turkeys. *Poultry science*, 67(10):1372-1377.
31. Bumstead N, Reece R, Cook J K (1993) Genetic differences in susceptibility of chicken lines to infection with infectious bursal disease virus. *Poultry science*, 72(3):403-410.