

PAPER • OPEN ACCESS

Comparative histological study of skin in Jenubi and its crossbreed cow

To cite this article: A Alsodany *et al* 2019 *J. Phys.: Conf. Ser.* **1234** 012067

View the [article online](#) for updates and enhancements.



IOP | ebooks™

Bringing together innovative digital publishing with leading authors from the global scientific community.

Start exploring the collection—download the first chapter of every title for free.

Comparative histological study of skin in Jenubi and its crossbreed cow

A Alsodany¹, K Alderawi² and A Mraisel³

¹Department of Biology, Science College, Misan University, Iraq

²Department of Biology, Science College, Basrah University, Iraq

³Department of Basic Medical Science, Nursing College, Misan University, Iraq

Histologist2018@gmail.com

Abstract. The aim of this study was to comparative the histological structure of skin in Jenubi cow and its Friesians crossbreed cow. Samples of skin were collected from abdominal regions of Jenubi cow and its Friesians crossbreed cow immediately after slaughter in Governorate of Misan. The results showed similarities in the structure of the normal skin layers which consists of three layers epidermis, dermis and hypodermis. Sweet glands were more distributed in the region between papillary and reticular layer and are associated with hair follicles. The primary hair follicle was associated with Sebaceous glands which were scattered in the deeper part of the reticular layer in both Jenubi and cross breed skin. The difference found in the micrometrical observations in the dermal layer, these variations between breeds in epithelium thickness of sweet glands were small in Jenubi cow while the epithelium thickness of crossbreed cow was more greater. The present study it was revealed that the sweat gland diameter in the skin of Jenubi cow was lower than in crossbreed cow. The conclusion of this study revealed that the location of the papillary layer is superficial and just under the basement membrane while the reticular layer composed the deeper layer in the dermis. The type of sebaceous gland was a simple, branched or compound. The epithelium thickness of sweet glands in crossbreed cow was more greater than Jenubi cow.

1. Introduction

All mammals are covered with skin which accounting for about 15% of the total adult body weight. It performs many vital functions, including the first line of defense against the invading pathogenic macro and microorganism as well as prevention of excess water loss from the body and a role in thermoregulation [1].

Heat tolerance it is the ability of the animals to withstand heat when all other factors are constant. Zebu breeds of cattle are more heat tolerant than temperate breed of cattle [2]. The main local Iraqi cattle breeds are: Jenubi, Karadi, Sharabi and Rustagi. It was reported that local Iraqi cattle are genetically resistant to endemic diseases and harsh environment. The main location of Jenubi cow is the South of Iraq. The studies about Jenubi cow was very rare and sporadic. The Specific visible traits Zebu breed. They are unicoloured, usually red (golden to bright bay) or multicoloured, sometimes pied [3]. Friesians are occasionally crossed with local cattle specially with the Jenubi to produce 50% cross which is sometimes upgraded to higher level through A.I. using Friesian semen.



The Ministry of Agriculture imported frozen semen from France representing a new breed for experimental study [3]. Characteristics of individual animals can also put them at higher risk for heat stress.

However, only few studies were performed to comparative the skin between Jenubi and crossbreed cow ,thus, the aim of this research was to comparative the histological Parameter (epithelium thickness of sweat gland, number of sweat glands ,number of sebaceous gland and number of hair follicle) of skin in Jenubi and Crossbreed cow to provide new data about the skin layers.

2. Materials and Methods

Samples of skin were collected from slaughters in Governorate of Misan, the samples were taken from abdominal regions immediately after slaughter of eight cows (4 Jenubi cows and 4 her Friesians crossbreed cows).The fresh tissue samples were fixed in 10%formalin,then all tissues were processed by routine Alcohol-Benzene schedule and molded in paraffin blocks for light microscopy study [4].

The paraffin blocks of the skin were cut by digital microtome in several serial incisions at 5-7 μm thickness for histological study .The sections were stained with Haematoxylin and Eosin [5,6]. The data obtained from micrometrical observations was analyzed statistically by two way ANOVA.

3. Results and Discussions

The results showed similarities in the structure of the normal skin layers in Jenubi and crossbreed cow which consists of three layers epidermis, dermis and hypodermis .The epidermis composed of stratified squamous keratinized epithelium, and these findings agree with [7] whose reported that in the skin of all mammals , the epidermis is a stratified squamous keratinized epithelium, as the first major layer.

From the present study it was revealed that the dermis consists of connective tissue divided in two parts layers :papillary and the reticular layer , as showed in figure1.

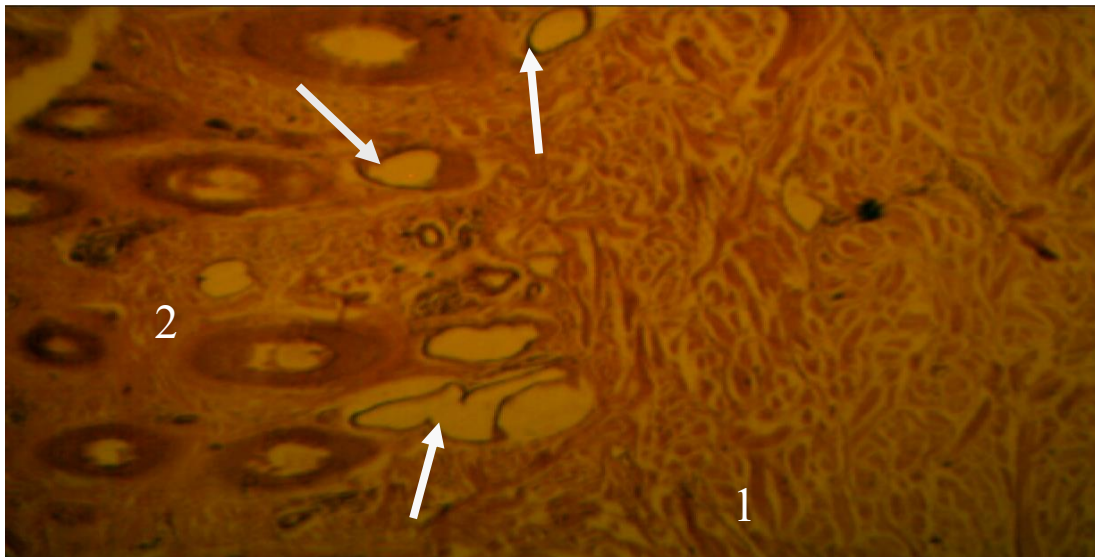


Figure 1. Skin of crossbreed cow white arrow show sweat glands 1- Papillary layer 2- Reticular layer . H&E X40.

These findings was in agreement with the observations by [8], who reported that the dermal components provide a combination of flexibility and tensile strength to the skin due to the abundance of the collagen .The location of the papillary layer is superficial and just under the basement membrane while the reticular layer composed the deeper layer in the dermis. Some authors [9] report that the reticular layer of the Sindhi breed increased in thickness as age advanced and the same trend

was observed in the Jersey breed, Jersey and Sindhi cross, Murrah buffalo as well as graded Murrah buffalo . In both Jenubi and cross breed the histological section of the dermis layer show sweat glands, sebaceous glands , hair follicles and blood vessels , as showed in figure 2.

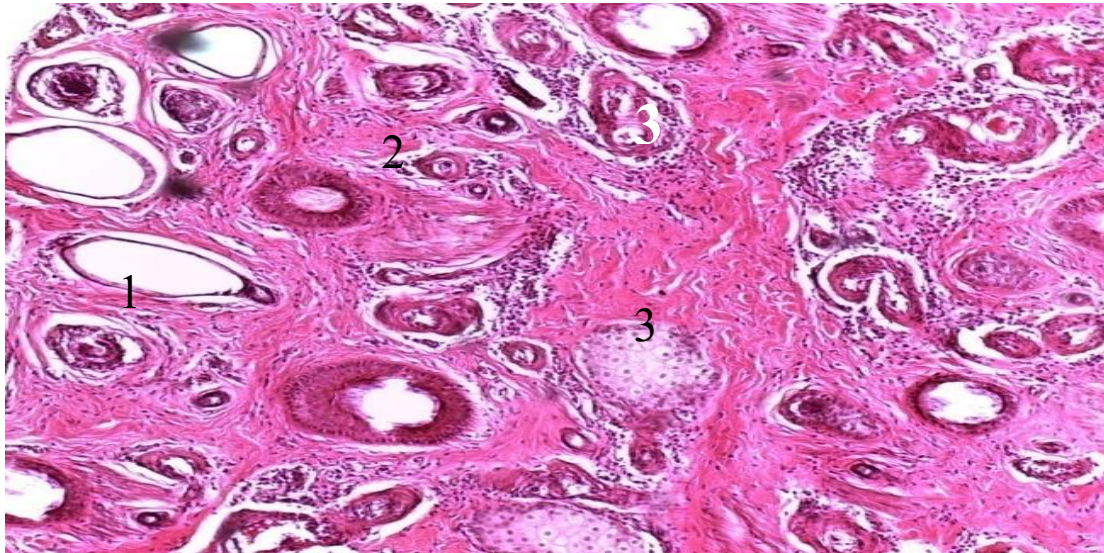


Figure 2. Dermis layer of Skin of crossbreed cow 1- sweat glands 2- hair follicle 3- sebaceous gland. H&E X100.

This finding is in accordance with observation reported by [10] Sweet glands was more distributed in the region between papillary and reticular layer and are associated with hair follicles and it is appeared as tubular and it was consisting of a secretory coil embedded in the dermis and lined by cuboidal cells , as showed in figures 3 and 4.

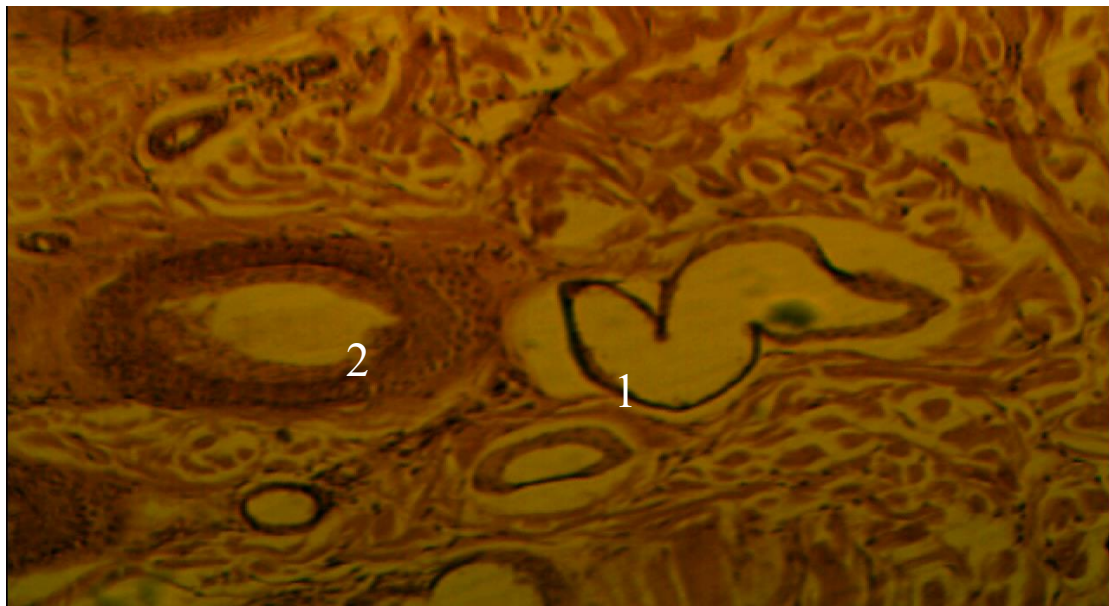


Figure 3. Dermis layer in skin of crossbreed cow 1- sweat glands 2- hair follicle . H&E X100.

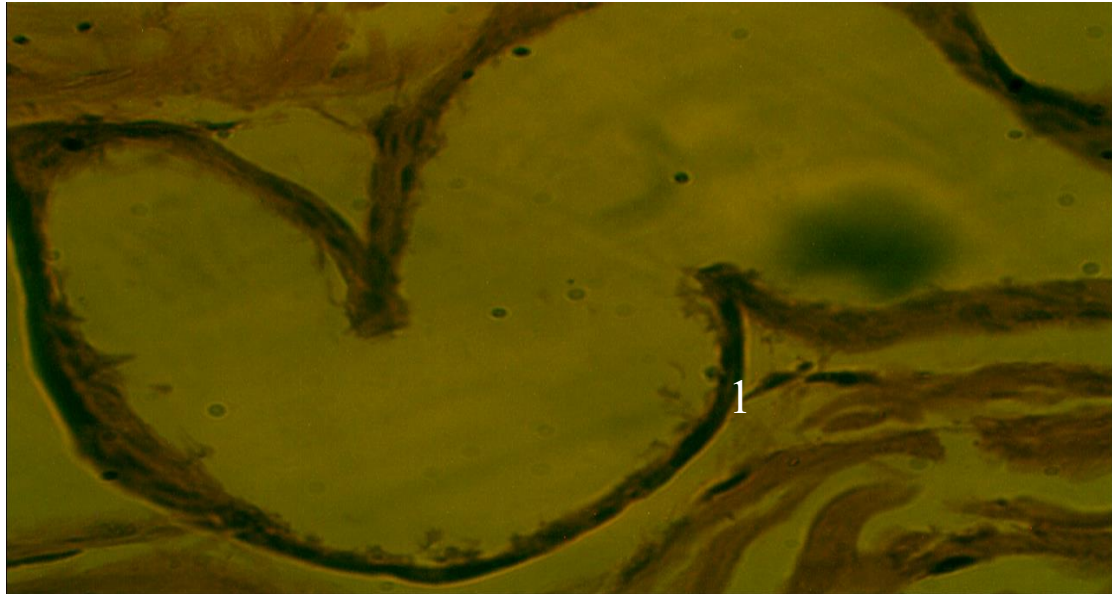


Figure 4. sweat glands of crossbreed cow 1- simple cuboidal epithelium of sweat gland .H&E X400.

In the study by [11] observed that the sweat glands of the skin were of simple coiled sacular glands consist of straight canal and coiled secretory portion, the gland density differs among animals, in buffalo it was few in number, single and showed low gland density and in cow has development sweat gland while were most numerous and form of aggregates wide spread in the dermis of camel skin.

Our data are consistent with the finding [12] that the primary hair follicle was associated with Sebaceous glands and there was arrangement observed of primary hair follicle with Sebaceous glands and 3-4 secondary follicles , as showed in figure 5.

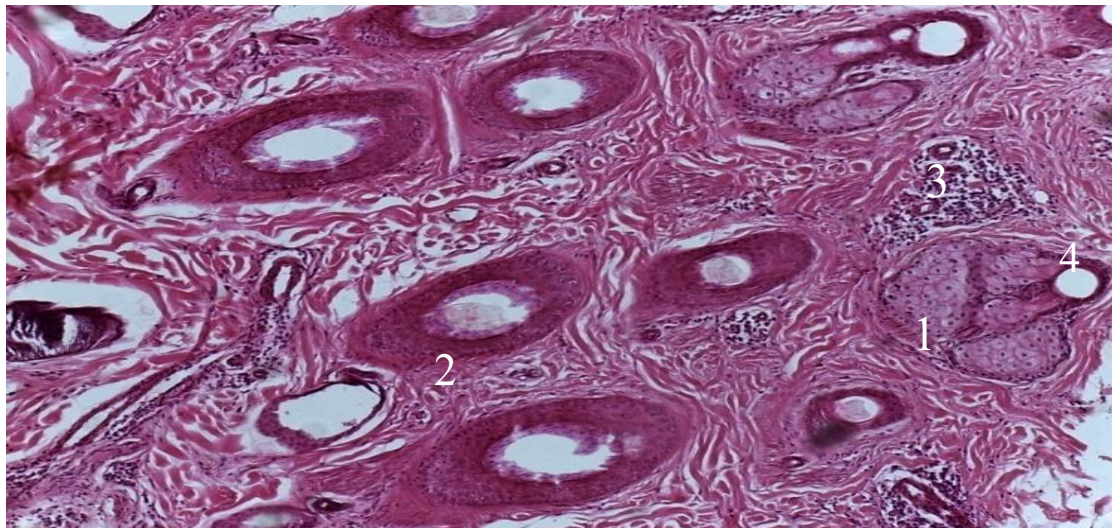


Figure 5. Dermis layer in Skin of Jenubi cow 1- sebaceous glands 2-secondary hair follicle 3-blood vessels 4- primary hair follicle. H&E X100.

The sebaceous glands in both Jenubi and cross breed skin were scattered in the deeper part of the reticular layer , as showed in figure 5 .It was observed that Sebaceous glands were found to be closely associated with most of the primary hair follicles, these findings in contrast with [13] who reported that sebaceous glands in the dermis of goat skin are associated with secondary hair follicle .

The type of sebaceous gland was a simple, branched or compound and the ducts gland was lining by simple cuboidal epithelium , as showed in figures 6,7 and 8.

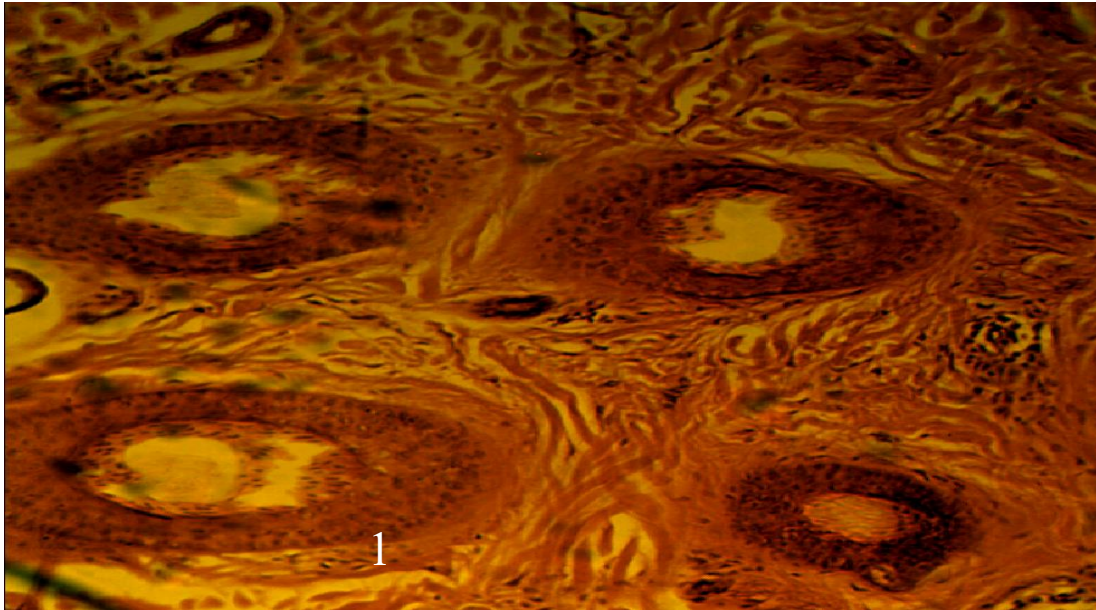


Figure 6. Secondary hair follicle of crossbred cow 1- arrector Pili muscle . H&E X100.

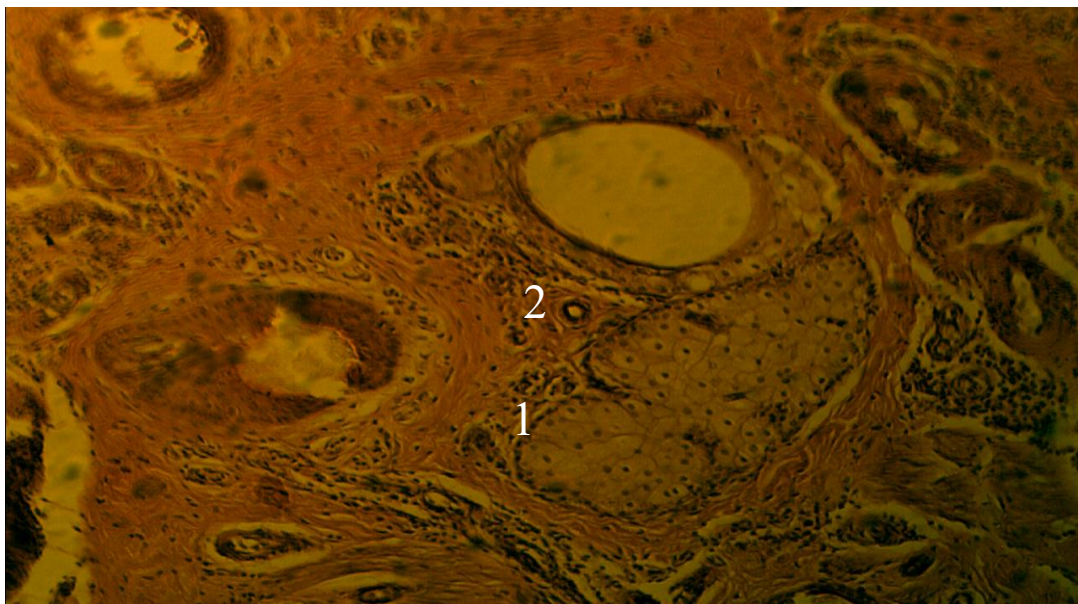


Figure 7. Dermis layer in Skin of Jenubi cow 1- simple cuboidal epithelium of sebaceous glands
2-blood vessels . H&E X100.

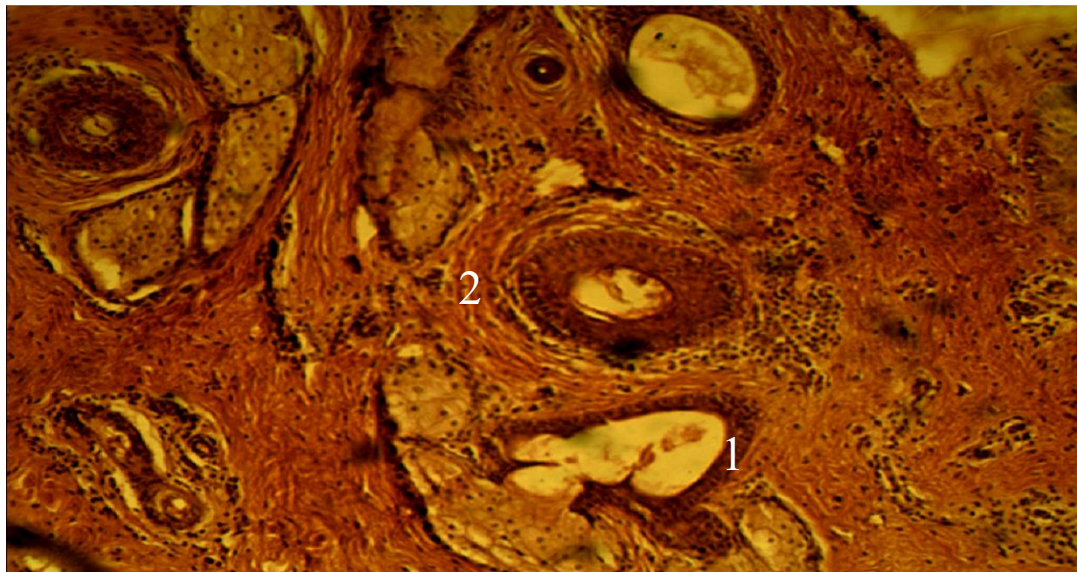


Figure 8. Dermis layer in Skin of Jenubi cow 1- simple cuboidal epithelium of sweat gland 2- arrector Pilli muscle . H&E X100.

Table 1 show the deference's were found in the micrometrical observations in the dermal layer. These variations between breeds in epithelium thickness of sweet glands , where it was $5\mu\text{m}$ in Jenubi while the epithelium thickness of crossbreed cow was more greater to reach $10\mu\text{m}$, and these differences may explain increase in sweat production and better heat resistance due to increase in the glandular portion and the reduction in height of glandular epithelium [14].

Table 1. Mean values of histological parameter measurements of skin in Jenubi and Crossbreed cow.

Histological Parameters	Jenubi cow Mean \pm SD μm	Crossbreed cow mean \pm SD μm
Epithelium thickness of sweet gland	5 ± 0.72	10 ± 0.51
Diameter of sweet gland	15 ± 0.52	20 ± 0.55
Number of sweet gland	17 ± 0.46	17 ± 0.44
Number of sebaceous gland	11 ± 0.58	11 ± 0.57
Diameter of sebaceous gland	21 ± 0.56	20 ± 0.53
Number of hair follicle	6 ± 0.64	9 ± 0.29

The present study it was revealed that the sweat gland diameter was $15\mu\text{m}$ in the skin of Jenubi cow was lower than in crossbreed cow which was $20\mu\text{m}$. The diameter in different regions for cattle not provided any conclusive effect region wise. Whatever the variations were observed that was only due to species difference [15].

4. Conclusion

Normal skin in Jenubi and crossbreed cow consists of three layers epidermis, dermis and hypodermis . The dermis consists of connective tissue divided in two parts layers :papillary and the reticular layer. The location of the papillary layer is superficial and just under the basement membrane while the reticular layer composed the deeper layer in the dermis. The primary hair follicle was associated with Sebaceous glands. The type of sebaceous gland is a simple, branched or compound .The epithelium thickness of sweet glands in crossbreed cow is more greater than Jenubi cow .

5. References

- [1] M.B. Hole, N.S. Bhosle and P.J. Kapadnis. 2008.Histological study of skin epidermis in red kandhari cows. *Indian J. Anim. Res.*, 42 (1) : 69-70 .
- [2] Singh S.V., Soren ,S. Beenam, A.K. Singh and Suresh Kumar .2013 .Heat Tolerance Indices for Cattle and Buffalo.Dairy Cattle Physiology Division,National Dairy Research Institute, Karnal-132001 (Haryana) India.
- [3] S.A. Magid,W.K. Al-Murrani and J. I. Alkas .2003. Iraq country report animal genetic resources.
- [4] LUNA,L.G., 1968. Manual of Histological Staining Methods of Armed Forces Institute of Pathology. Edn 3rd, McGraw Hill book Co, New York.
- [5] A. Mohamed .2015. lecture on routine histological techniques. National Library Cataloging-Sudan.
- [6]
- [7] H.M.Carleton and A.B.Drury. .957.Histological technique for normal and pathological tissues and the identification of parasite 3ed.London oxford university press , New York Toronto. Wakuri,H.,K.Mutoh, H. Ichikawa and B.Llu.1995.Microscopic Anatomy of the Equine Skin with Special Referenceto the Dermis. *Okajimas Folia Anat. Jpn.*, 72(2-3): 177-184.
- [8] S. Montell i, L.Corain, B. Cozz i, and A. Peruff .2015.Histological Analysis of the Skin Dermal Components in Bovin e Hides Stored under Different Conditions. *JALCA*, vol. 110.
- [9] M.R.Muralidharan1 and V.Ramesh.2005.Histological and biochemical studies of the skin of cattle and buffalo. *Indian J. Anim Res.*39(1) 41 - 44.
- [10] Raheeqa Razvia , Shalini Suria, Kamal Sarmaa and Rohin Sharmab .2015.Histomorphological and histochemical studies on the different layers of skin of Bakerwali goat. *Journal of Applied Animal Research*,
- [11] Saffia Kareem Wally Al- Umeri Nabeel Abd Murad Al- Mamoori.2016.Comparative histological and histochemical study of flank region skin, in camel, cow and buffalo.*AL-Qadisiyah Journal of Vet. Med. Sci.* Vol. 15 No. 2
- [12] Obayes A. K. 2016 .Histological Study for Skin of Horse Tikrit *Journal of Pure Science* 21 (1)
- [13] Y.B.Shambhulingappa,R.V.Prasad,K.V.Jamuna, ,M.Narayana and V. Ramkrishna .2014. Histological characteristics of hair follicle pattern in Indian bison (*Bos gaurus*),Black buck (*Antelope cervicapra*) and Nilgai (*Boselaphustragocamelus*) .*Veterinary World* , veterinary world.org/Vol.7/.
- [14] Mara Regina Bueno de Mattos Nascimento*1, Enéias Aurélio Dias2, Thaisa Reis dos Santos3,Gustavo Ferreira Ayres4, Carolina Cardoso Nagib Nascimento4, Marcelo Emílio Beletti5.2015. Effects of age on histological parameters of the sweat glands of Nellore cattle .*Rev. Ceres, Viçosa*, v. 62, n.2, p. 129-132,
- [15] Partha Das, Rajesh Ranjan, Susanta Paul.2014.Acomparative histological study on the sweat gland of cattle (*B.Indicus*)and yak (*P. Poepagus*). *Explor Anim Med Res*,Vol.4, Issue - 2, p. 183-187.