

STUDY THE EFFECT OF EXOGENOUS ESTROGEN ADMINISTRATION ON PROSTATE GLAND OF LABORATORY WHITE MICE (*MUS MUSCULAE*)

Mukhallad A. Ramadhan

Department of Pathology, College of Medicine, University of Missan, Missan, Iraq

(Received 17 February 2013, Accepted 26 March 2013)

Keywords; estrogen, ESR1, prostate

ABSTRACT

A substantial advance in our understanding on the estrogen signaling occurred in the last decade. Estrogens interact with two receptors, ESR1 and ESR2, also known as ER α and ER β , respectively. ESR1 and ESR2 belong to the nuclear receptor family of transcription factors. 24 male mice divided into four groups as following : negative control, low dose group, intermediate dose group and high dose group, the groups of treatment were injected with estrogen at different doses while the negative control group were injected with normal saline (by method of intramuscular injection for all groups) and after 6 weeks all animals had been killed and the prostate was picked up and sectioned to reveal the histopathological changes. the study found that the injection of exogenous estrogen result in marked hyperplasia of the prostatic tissue and the hyperplasia increased significantly with elevation of the estrogen dose. In conclusion injection of exogenous estrogen lead to prostate hyperplasia through its action on the estrogen receptors which present in both stromal and epithelial component of the prostate.

INTRODUCTION

It is known that there are both significant similarities in the gross and microscopic anatomy of the mouse and the human prostates, and these need to be considered when evaluating murine models of human prostatic disease. Both mouse and human have similar epithelial cell types present in their prostates (secretory, basal and neuroendocrine), which presumably carry out the same physiological functions, but the ratio varies between species. Both species have columnar secretory epithelial cells which secrete prostatic proteins and fluids from their apical surfaces into a lumen. Humans have a continuous layer of basal cells between the secretory cells and

the basement membrane, whereas mice have fewer basal cells and a discontinuous layer around the glands (1). Neuroendocrine cells are scattered and rare in human prostate, and even more rare in the mouse (2). The prostates of both species are composed of glands and ducts, but there are significant differences in the stroma. The human prostate has a robust fibro muscular stroma. The mouse prostate has a very modest stromal component. Both species have prostates and accessory glands that develop from Wolffian ducts and urogenital sinuses and both are androgen-sensitive (3). There are many embryological, anatomical and histological similarities between mouse and human prostate tissues (4).

The etiology of benign prostate hyperplasia (BPH) is still poorly understood, it is thought to be related to the combination of aging and endocrine dysregulation (5). It is well documented that androgens are the primary factor for prostate disease (6), but the mechanism is still unclear (7). While the prostate is considered the prototype androgen-dependent gland, there is rising evidence that estrogen is necessary to maintain the natural function of prostate (8,9). In addition, estrogens also play an important role in growth and differentiation of prostate gland (10).

Prostate tissue is also most probably a target for direct regulation by estrogens. Prostate contains estrogen receptor ($ER\alpha$) and ($ER\beta$), which are localized characteristically in stroma and epithelium, respectively (11). The physiological function of these receptors is not known but there is evidence of the role of estrogens in prostatic hyperplasia and carcinogenesis. Developing prostate seems particularly sensitive to increased level of endogenous and/or exogenous estrogens (12). So this study had been accomplished in order to confirm that elevation of the serum level of estrogen cause benign prostate hyperplasia.

MATERIALS AND METHODS

Twenty four male laboratory mice were divided into four groups each group consist of six animals, the animals of each group were housed together in same conditions with free access of food and water. The groups of animals include : negative control group in which the animals injected with normal saline, low dose group, animals in this group were injected with (5 mg/ kg), intermediate dose group, in which the animals injected with (10 mg/kg) which is the therapeutic dose of the

estrogen, high dose group, animals were injected with (20 mg/kg) by intramuscular injection for all groups.

animals of all groups injected with estrogen daily for six weeks and the animals observed clinically all period of treatment, then the animals had been killed and the prostate collected and sectioned in the pathology laboratory and stained with routine (H&E) stain to reveal the histopathological changes.

RESULTS

The behaviors of the animals in the negative control group appear normal as well as the histology of the prostate appear with normal limits as shown in the figures (1,2).

The daily clinical observation of the animals of the low dose groups revealed that these animals showed some difficulties in the urination appear in the fifth week of administration which indicated by interrupted urination and this sign continue till the end of experiment.

Histopathological inspection revealed that the ventral and dorsal prostate show slight thickening in the Stroma with mild hyperplasia of the glandular epithelium as shown in the figures (3,4).

Clinical observation of the animals of intermediate group reveal that these animals show some difficulties in the urination started in the fourth week then urine retention appear in the sixth week in which the animals were assisted to urinate by continues massage for the urethra and bladder from the abdominal wall.

Microscopic inspection reveal that the prostate tissue shows marked hyperplasia in the glandular tissue with multiple layers of cells instead of single layer with stromal thickening as shown in the figures (5,6,7).

The clinical observation of the animals in the group of high dose revealed the difficulties in the urination appeared in the third week, then urine retention appear in the fourth week, the urinary bladder was palpable because it was over distended with urine as shown in the figure (10) and it was very difficult to assist the animal for urination even by the massage of the bladder and urethra.

Histopathological examination reveal that the prostate tissue appear with marked hyperplastic epithelium with papillary projections to the lumen of the gland

which is nearly completely close the lumen and stromal thickening as shown in the figures (8,9).

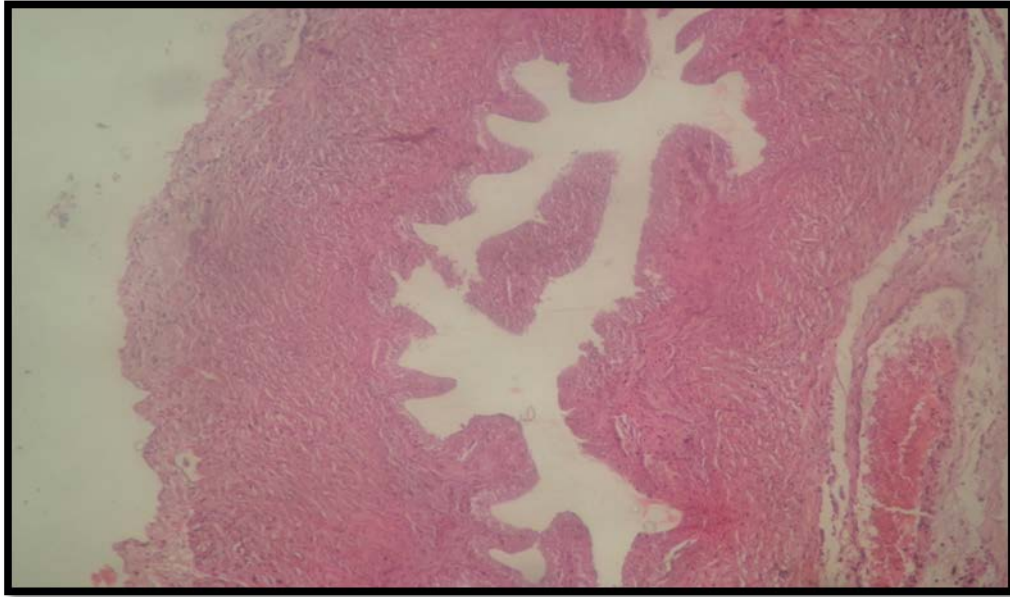


Fig (1) Normal histological appearance of the ventral prostate (H&E, 50X)

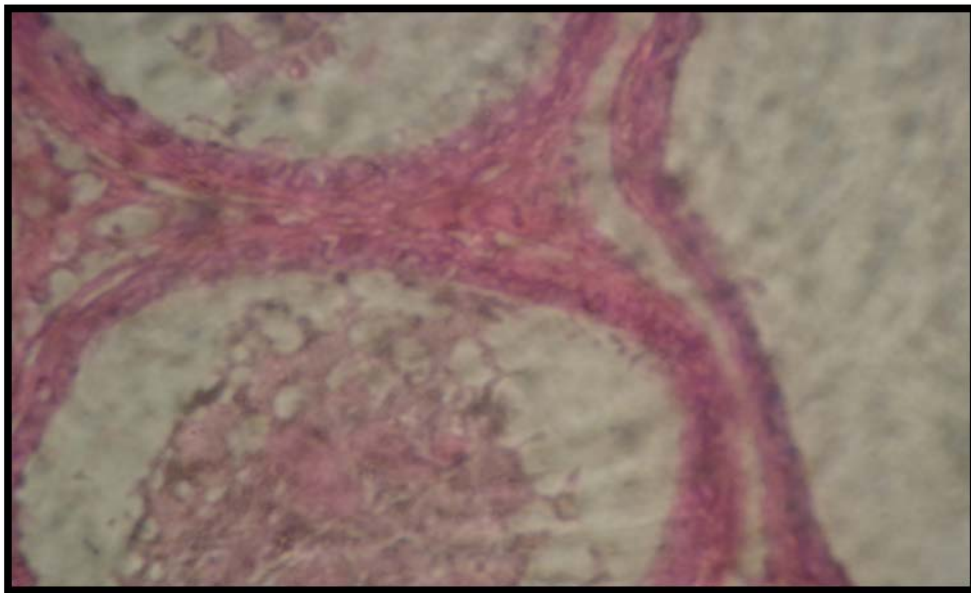


Fig (2) Normal histological appearance of the dorsal prostate (H&E, 500X)

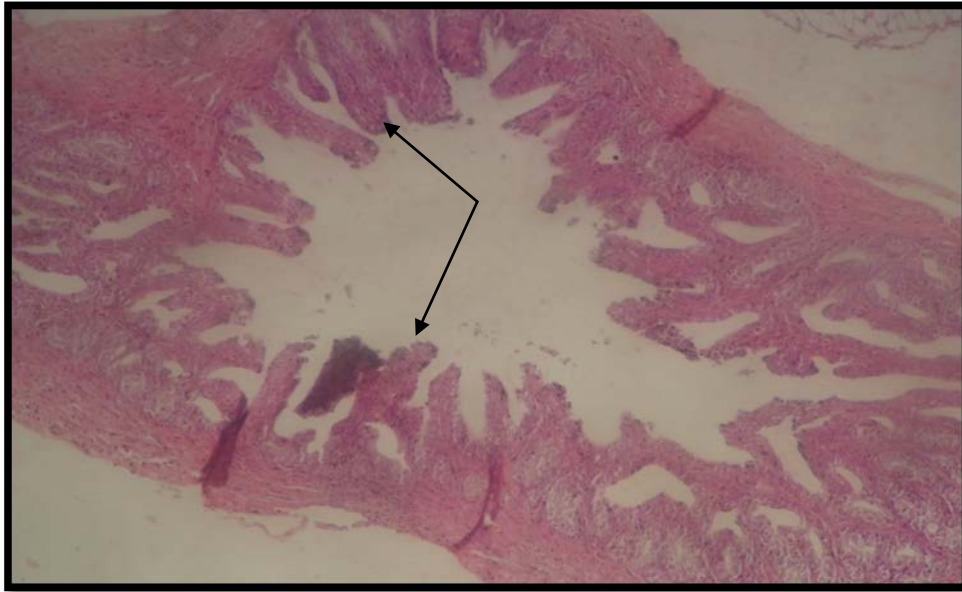


Fig (3) prostate of low dose group reveal hyperplasia of the prostate epithelium which appears as finger like projections (H&E, 50X)

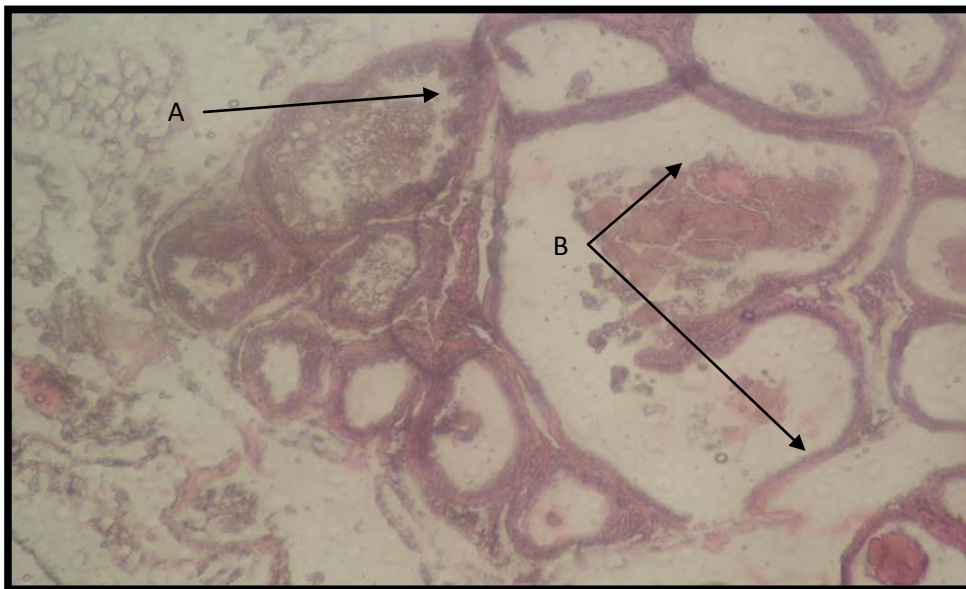

Fig (4) prostate of low dose group reveal A) Hyperplasia of the prostate epithelium indicated by thickening of the epithelium B) Cystic dilation of some glands (H&E, 50X)

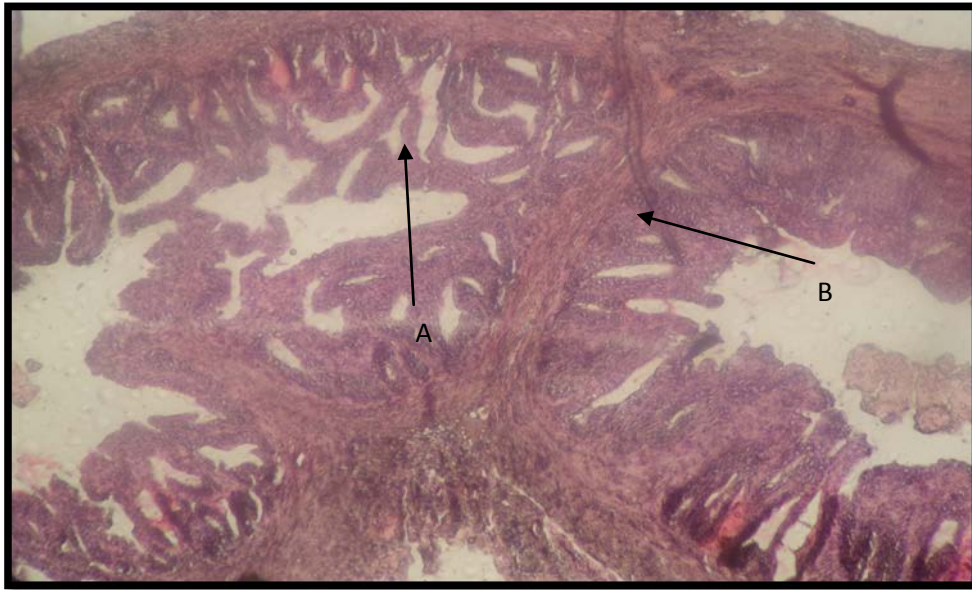


Fig (5) Prostate of intermediate dose group reveal marked A) Hyrperplasia of the prostate epithelium which appears as finger like projections B) Compression of the stroma in the center (H&E, 50X)

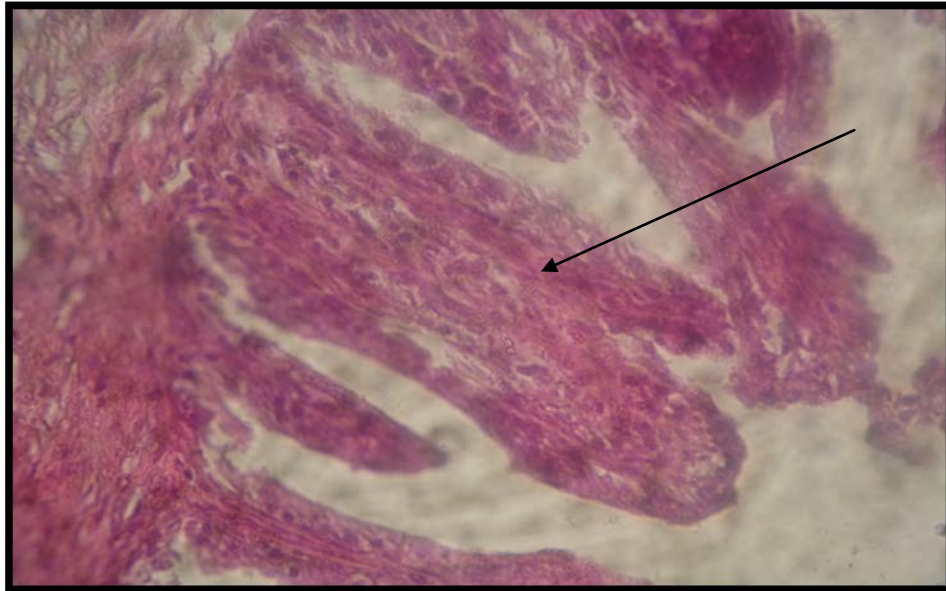


Fig (6) Prostate of intermediate dose group reveal hyrperplasia of the prostate epithelium which appears as extentions toward the lumen (H&E, 500X)

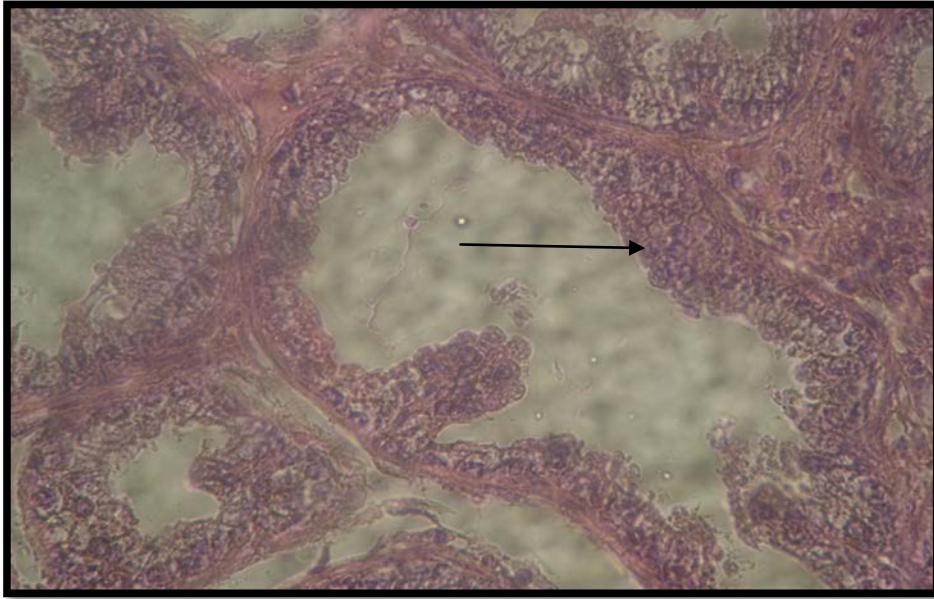


Fig (7) Prostate of intermediate dose group reveal hyperplasia of the prostate epithelium which appears multiple layers instead of single layer that lead to narrowing of the glandular lumen (H&E, 500X)

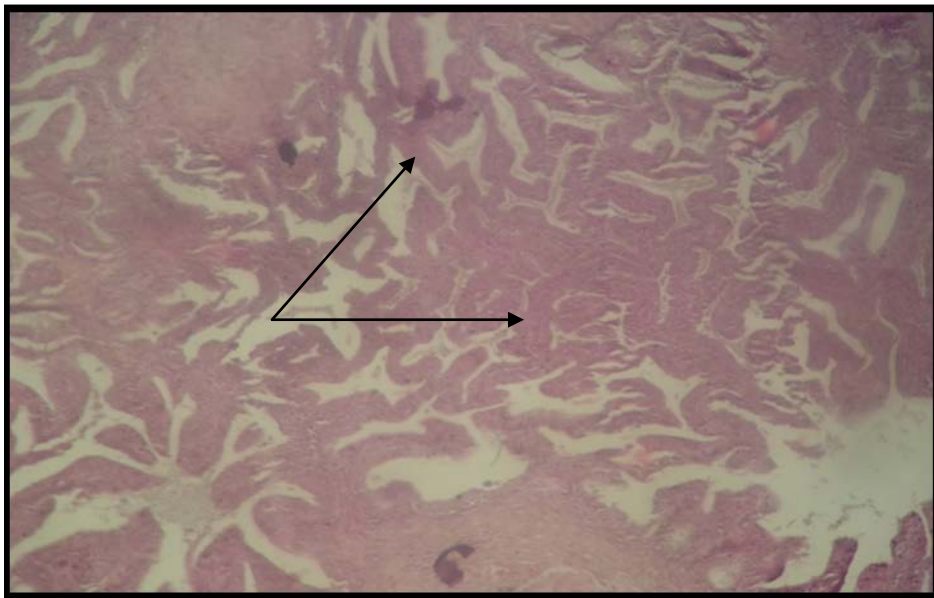


Fig (8) Prostate of high dose group reveal marked hyperplasia of the prostate epithelium which appears as extensions nearly completely fill the lumen of the gland with thickening of the stroma (H&E, 50X)

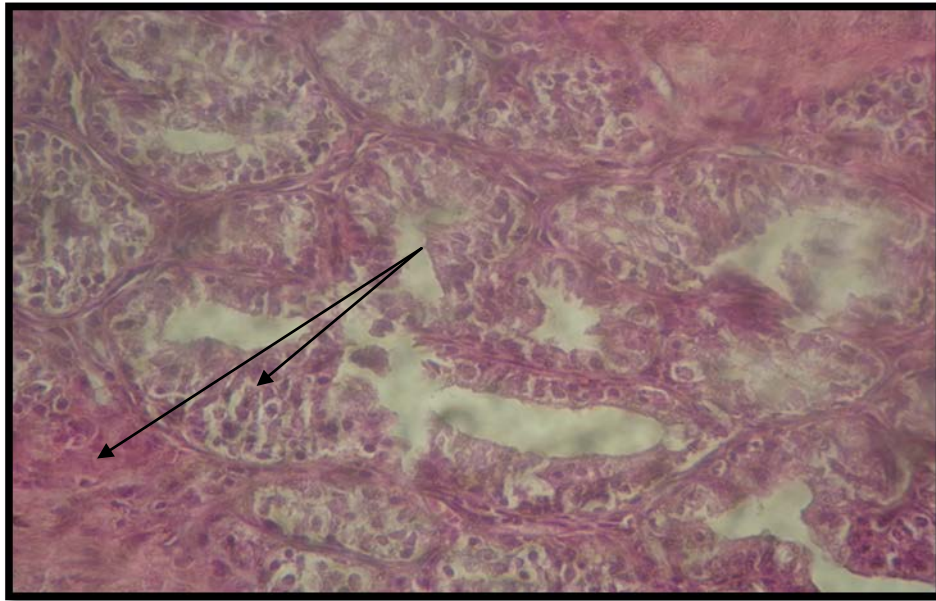


Fig (9) Prostate of high dose group reveal marked hyperplasia of the prostate epithelium which appears as multiple layers cause narrowing of glandular lumen with thickening of the stroma (H&E, 500X)

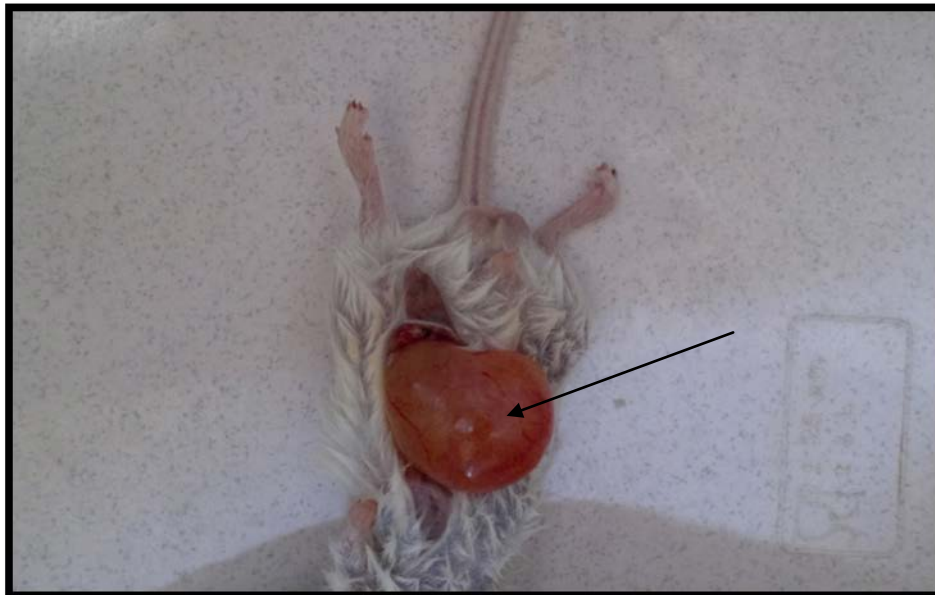

Fig (10) Gross appearance of the animal at time of killing which reveal overfilling of the bladder with urine due to obstruction of urine outflow by enlargement of the prostate.

DISCUSSION

The present study tends to evaluate the effect of elevated estrogen levels in the blood on the prostatic tissue since the prostate have a widely distributed Estrogen receptors in both epithelium and stroma (13), and the causes of benign prostate hyperplasia still controversial matter. so the present study tend to confirm that the elevation of the estrogen level is one of the considerable causes for this common pathological conditions in the human particularly in the middle age and elderly persons through working on experimental animals.

Estrogens, acting via estrogen receptors (ER) α and β , exert direct and indirect actions on prostate growth and differentiation (14). The presence of estrogen receptors in prostate suggests that estrogens may act directly on multiple sites in prostate. Interestingly, the two ER subtypes have very different expression patterns. In human and rodent prostate, ER β is the predominant ER subtype, expressed in the majority of the epithelial cells, as well as in some stromal cells (15). ER α is expressed in a more limited manner, and typically found in stromal cells only. However, ER β -positive cells are found in hyperplastic or metaplastic epithelium in the prostatic ducts and posterior periurethral region, but the functional relevance of this observation is still unclear (12). Previous studies using animal models to determine the role of ER β in the prostate have been problematic because the centrally mediated response to estrogen results in reduced androgen levels and prostatic epithelial regression, potentially masking any direct effects via ER β , but the recent studies reveal that ER α was expressed only in the stromal cells of peripheral zone (PZ) but not of transitional zone (TZ). In contrast, ER β expression was detected in a wide variety of prostate cells, including glandular epithelial cells, basal cells, and stromal cells (13). So the present study which use different doses of estrogen result in variable degrees of prostate hyperplasia come in consistent with the interpretations of the previous studies which reported the distribution of the estrogen receptors in different sites of the prostate tissue particularly the transitional zone (16), which is the common site for benign prostate hyperplasia play a very important role in the development of this pathologic condition in case of elevated estrogen level.

دراسة تأثير الحقن الخارجي للاستروجين على غدة البروستات في الحيوانات المختبرية البيضاء

مخلد عبد الكريم رمضان

فرع الامراض، كلية الطب، جامعة ميسان، ميسان، العراق.

الخلاصة

هناك تقدم كبير في فهمنا لانتقال الإشارات الخلوية الناتجة من اتحاد الاستروجين بمستقبلاته قد حدث في الآونة الأخيرة، حيث وجد إن الاستروجين يتفاعل مع نوعين من مستقبلاته والتي تسمى (مستقبلات الاستروجين 1) و(مستقبلات الاستروجين 2) أو (مستقبلات الاستروجين نوع α) و(مستقبلات الاستروجين نوع β)، وهذه المستقبلات تعود لعائلة المستقبلات النووية لعوامل النسخ. استخدم في التجربة 24 فأراً مختبرياً ذكراً قسمت إلى أربعة مجاميع وهي كالتالي: مجموعة السيطرة السالبة، مجموعة الجرعة المنخفضة، مجموعة الجرعة المتوسطة أو الجرعة العلاجية للاستروجين، مجموعة الجرعة العالية حيث حقنت المجاميع الثلاثة الأخيرة بجرع مختلفة من الاستروجين بينما مجموعة السيطرة السالبة حقنت بالمحلول الفسلجي المتعادل (بطريقة الحقن بالعضل لجميع المجاميع) وبعد 6 اسابيع تم قتل جميع حيوانات التجربة واخذ نسيج البروستات و تم تقطيعه وتم دراسة التغيرات النسجية. اظهرت النتائج ان حقن جرع من الاستروجين ادى الى فرط تنسج ملحوظ في النسيج البروستاتي، وان فرط التنسج هذا كان متزايداً بشكل ملحوظ مع زيادة جرعة الاستروجين. نستنتج من ذلك ان حقن كميات من الاستروجين تؤدي الى فرط تنسج البروستات من خلال تأثيره المباشر على مستقبلات الاستروجين المتواجدة في كل من سدى و الخلايا الضهارية للبروستات.

REFERENCES

- 1- Marker, P.C.; Donjacour, A.A.; Dahiya, R. and Cunha, G.R. (2003). Hormonal, cellular, and molecular control of prostatic development. *Developmental Biology*. 253: 165–174.
- 2- Garabedian, E.M.; Humphrey, P.A. and Gordon, J.I. (1998). A transgenic mouse model of metastatic prostate cancer originating from neuroendocrine cells. *PNAS* 95: 15382–15387.
- 3- Roy, B. P.; Zheng, J. and Miller, G.J. (1997). Molecular heterogeneity in prostate cancer: can TP53 mutation unravel tumorigenesis? *Molecular Medicine Today*. 3: 476–482.
- 4- Roy, B. P.; Wu, H. C. Powel, I.I.; Hagenkord, C. H. and Cohen, M. B. (2004). Genetically defined mouse models that mimic natural aspects of human prostate cancer development. *Endocrine-Related Cancer*. 11: 225–254.

- 5- **Chu, J.H.; Sun, Z.Y.; Meng, X.L.; Wu, J.H.; He, G.L. and Liu, G.M. (2006).** Differential metastasis-associated gene analysis of prostate carcinoma cells derived from primary tumor and spontaneous lymphatic metastasis in nude mice with orthotopic implantation of PC-3M cells. *Cancer Lett.* 233: 79 – 88.
- 6- **Qian, L.H. and Wang, X.L.; Tu, Z.H. (2001).** Inhibition of re growth of prostatic glandular cells by epristeride. *Acta. Pharmacology Sin.* 22: 847 – 50.
- 7- **Meigs, J.B.; Mohr, B.; Barry, M.J.; Collins, M.M.; McKinlay, J.B. (2001).** Risk factors for clinical benign prostatic hyperplasia in a community-based population of healthy aging men. *J. Clin. Epidemiol.* 54: 935 – 44.
- 8- **Griffiths, K. (2000).** Estrogens and prostatic disease. International Prostate Health Council Study Group. 45: 87 – 100 .
- 9- **Pettersson, K. and Gustafsson, J.A. (2001).** Role of estrogen receptor beta in estrogen action. *Annu Rev Physiol* 63: 165 – 92.
- 10- **Liu, X.Y.; Xu, Y.W.; Xie, C.J.; Wang, J.J.; Pan, Q.; Gui, B. and Sun, Z.Y. (2010).** Possible mechanism of benign prostatic hyperplasia induced by androgen-estrogen ratios in castrated rats. *J. pharmacology.* 42,5: 312 – 317.
- 11- **Maria, F. L.; Thais, L.; Fabiana, Y.; Gisele, R. G.; Erica, R. S.; Carine, R.; Sheilla, A. F. and Catarina, S.P. (2009).** Estrogen receptors and function in the male reproductive system. *Arq. Bras Endocrinol Metab.* 53: 8 - 18.
- 12- **Pirkko, L. and H'ark'onen, S. I. (2004).** Role of estrogens in development of prostate cancer. *J. Steroid Biochemistry & Molecular Biology.* 92: 297–305.
- 13- **Toshifumi, T.I.; Daiuy, A.I.; Hiroshi, K.E.; Satoshi, I.E.; Masami, M.U.; Yoshitaka, H.A. and Takehiko, K.I. (2003).** Zone-Dependent Expression of Estrogen Receptors α and β in Human Benign Prostatic Hyperplasia. *J. Clinical Endocrinology & Metabolism* 88(3): 1333 – 1340.
- 14- **Stephen, J.; Stuart, J.; Evan, R. S.; Vladimir, P.; Karl, H. F. and Gail, P. R. (2007).** Epithelial Regulation of Prostatic Hyperplasia. *J. Endocrinology* 148(2): 566–574.
- 15- **Nishihara, E.; Nagayama, Y.; Inoue, S.; Hiroi, H.; Muramatsu, M.; Yamashita, S. and Koji, T. (2000).** Ontogenic changes in the expression of estrogen receptor α and β in rat pituitary gland detected by immunohistochemistry. *Endocrinology* 141: 615–620.
- 16- **Enmark, E.; Pelto, H. M.; Grandien, K.; Lagercrantz, S.; Lagercrantz, J.; Fried, G.; Nordenskjold, M. and Gustafsson, J.A . (1997).** Human estrogen receptor _ gene structure, chromosomal localization, and expression pattern. *J. Clin Endocrinol Metab* 82: 4258–4265.